



**Western University**

---

**From the Selected Works of Tony Rupar**

---

2022

# An Unexpected Finding of Hepatosplenomegaly in a Pediatric Patient

Tony Rupar, *Western University*

Hailey Barootes, *Western University*

Chitra Prasad

Dhandapani Ashok, *Western University*


# An Unexpected Finding of Hepatosplenomegaly in a Pediatric Patient

Clinical Pediatrics  
2022, Vol. 61 (1) 81–85  
© The Author(s) 2021



Article reuse guidelines:  
sagepub.com/journals-permissions  
DOI: 10.1177/00099228211059668  
journals.sagepub.com/home/cpj



Hailey C. Barootes, MBChB<sup>1</sup> , Chitra Prasad, MD, FRCPC, FCCMG<sup>2</sup>,  
C. Anthony Rupar, PhD, FCCMG<sup>1</sup>,  
and Dhandapani Ashok, MBBS, MD, FRCPC<sup>1</sup>

## Abstract

Gaucher disease (GD) is a rare autosomal recessive metabolic disorder. It is characterized by a deficiency of lysosomal glucocerebrosidase, which results in the accumulation of glycosphingolipid substrates, primarily glucosylceramide, in the phagocyte system. In GD Type 1, the liver, spleen, and bone marrow are typically affected. We report the case of a 7-year-old female with GD Type 1 who presented with hepatosplenomegaly detected incidentally following a motor vehicle accident. She was found to have concomitant thrombocytopenia and Erlenmeyer flask deformities of her lower limbs. Diagnosis was made on the basis of very low leukocyte  $\beta$ -glucocerebrosidase activity and elevated plasma chitotriosidase. DNA mutation studies revealed both c.1226A>G and c.116\_1505 deletion (exons 3-11). The patient is currently managed with biweekly intravenous imiglucerase (Cerezyme) replacement therapy. She demonstrated resolution of thrombocytopenia and hepatosplenomegaly at 2-year follow-up. Physicians must consider this rare diagnosis in children presenting with hepatosplenomegaly to prompt timely management.

## Keywords

Gaucher disease, lysosomal storage disease, hepatosplenomegaly, imiglucerase replacement therapy

## Introduction

Gaucher disease (GD) is the most common lysosomal storage disorder.<sup>1</sup> It is autosomal recessively inherited and results from pathological variants in the *GBA* gene, which codes for the lysosomal enzyme  $\beta$ -glucocerebrosidase (acid  $\beta$ -glucosidase). Deficiency of this enzyme results in accumulation of its major substrate, glucocerebroside, within the lysosomes of macrophages. These pathologic macrophages, known as Gaucher cells, infiltrate the liver, spleen, bone marrow, lungs, and occasionally nervous system.<sup>1</sup>

There are 3 main types of GD, including nonneuronopathic (Type 1), acute neuronopathic (Type 2), and chronic neuronopathic (Type 3). Type 1 is the most prevalent and accounts for up to 90% of all cases.<sup>2</sup> It is characterized by multisystem involvement including hepatosplenomegaly, bony pain, osteonecrosis, pathological fractures, anemia, thrombocytopenia, fatigue, and failure to thrive.<sup>2</sup>

Enzyme replacement therapy (ERT) with intravenous recombinant mannose-terminated glucocerebrosidase is first-line treatment for GD Type 1. Due to its reversible effects on visceral damage, ERT has the potential to

reduce hepatosplenomegaly, minimize skeletal pathology, correct anemia and thrombocytopenia, and optimize growth.<sup>3</sup> In this report, we describe a rare case of incidentally detected GD Type 1 treated with imiglucerase replacement therapy.

## Case Presentation

A 7-year-old female was referred to the Paediatric Liver Clinic for hepatosplenomegaly found incidentally on assessment following a minor motor vehicle accident. The patient was asymptomatic aside from endorsing a history of easy bruising, pain to her upper and lower

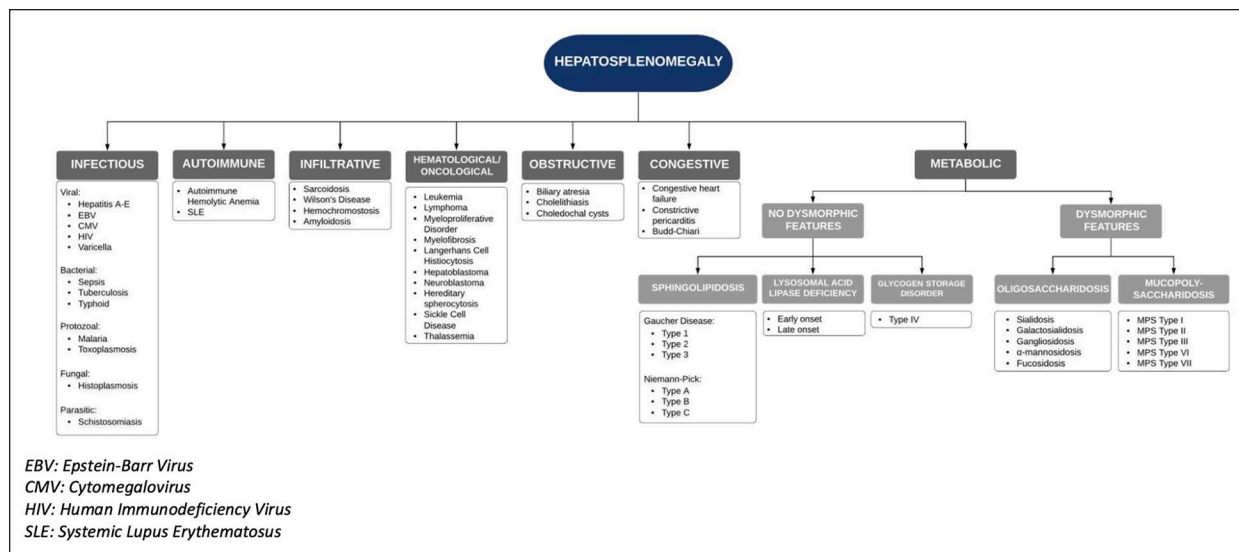
<sup>1</sup>Children's Hospital, London Health Sciences Centre, Western University, London, Ontario, Canada

<sup>2</sup>Children's Health Research Institute, Western University, London, Ontario, Canada

### Corresponding Author:

Dhandapani Ashok, Department of Paediatrics, Division of Paediatric Gastroenterology, Children's Hospital, London Health Sciences Centre, 800 Commissioners Rd E, London, Ontario, Canada N6A 5W9.

Email: Dhandapani.Ashok@lhsc.on.ca



**Figure 1.** Approach to hepatosplenomegaly in pediatric patient.

Abbreviations: EBV, Epstein-Barr virus; CMV, cytomegalovirus; HIV, human immunodeficiency virus; SLE, systemic lupus erythematosus.

limbs, and occasional epistaxis. Developmentally, she was age appropriate with no neurological symptoms, fevers, weight loss, night sweats, or manifestations of chronic liver disease. Her past medical history was significant only for asthma and recurrent tonsillitis. The patient's parents were nonconsanguineous. Her mother was of Scottish, Irish, and possibly Turkish descent, and her father was Ethiopian. Family history was significant for amyotrophic lateral sclerosis in the biological father.

On physical examination, the patient's vital signs were stable. Her weight was 23.7 kg (50th percentile) and height was 118.3 cm (15th percentile). She did not have any dysmorphic features. Her abdomen was soft and nontender with a liver palpable 4 cm below the right costal margin. Her splenic edge was palpable at the umbilicus. There was no evidence of anemia, jaundice, finger clubbing, or lymphadenopathy. Neurological examination was unremarkable.

An ultrasound of her abdomen demonstrated an elongated spleen of 16 cm and liver of 14 cm. Parenchymal echogenicity of the liver and spleen were satisfactory. Color Doppler studies did not detect any hemodynamic lesions. As seen in Figure 1, the differential diagnosis for hepatosplenomegaly is broad.

As such, initial laboratory investigations were performed in the Paediatric Liver Clinic (Table 1). An infectious screen revealed a negative heterophile antibody test and nonreactive hepatitis A, B, and C serology. An immunological liver workup revealed normal immunoglobulins, C3 and C4, antinuclear antibody, anti-double stranded DNA, anti-MPO, anti-PR3,  $\alpha$ -1-antitrypsin, and ceruloplasmin. Hematological investigations including

hemoglobin electrophoresis, Coomb's test, and G6PD deficiency screen were also negative. An  $\alpha$ -fetoprotein level was also unremarkable. Metabolic storage disease was suspected, and testing revealed low leukocyte  $\beta$ -glucocerebrosidase activity and high plasma chitotriosidase activity (Table 1). In the context of hepatosplenomegaly, bony pain, easy bruising, and occasional epistaxis, we made a diagnosis of GD Type 1.

The patient was referred to the Paediatric Metabolic Genetics team for further assessment. DNA sequencing of *GBA* identified 2 pathogenic variants, c.1226A>G and c.116\_1505 deletion, confirming a diagnosis of GD Type 1. The c.1226A>G p.(N 409S; also known as N370S) is a common pathogenic variant. The c.116\_1505 deletion is a novel deletion that spans exons 3 to 11 of *GBA*. A whole-body magnetic resonance imaging was performed to assess for bony abnormalities and identified mild femoral Erlenmeyer flask deformities bilaterally.

## Final Diagnosis

Gaucher disease Type 1.

## Course in Hospital

The patient was started on ERT with imiglucerase (Cerezyme) at 60 U/kg every 2 weeks. She tolerated this well with no reported side effects. Two years later, she continues to thrive with a weight of 28.4 kg (69th percentile) and height of 122.6 cm (15th percentile). Clinical examination and a repeat abdominal

**Table 1.** Laboratory Investigations.

Investigation	At presentation	After 2 years of ERT	Normal range
LKC ( $\times 10^9/L$ )	6.0	10.0	5-12
Hg (g/L)	113	118	110-160
Plt ( $\times 10^9/L$ )	127	172	150-400
Reticulocytes (/L)	81		10-100
UBIC ( $\mu\text{mol/L}$ )	68.2	47.3	24.2-70.1
Transferrin saturation (%)	13.1	16.3	11.0-56.0
Ferritin ( $\mu\text{g/L}$ )	157	152	13.0-92.0
Iron ( $\mu\text{mol/L}$ )	10	10	7-26
INR	1.2		0.9-1.1
PTT (seconds)	30		20-29
Fibrinogen (g/L)	2.28		1.70-4.20
ALT (U/L)	58	31	$\leq 33$
AST (U/L)	86	37	$\leq 32$
ALP (U/L)	266	231	142-335
GGT (U/L)	27	10	$\leq 40$
LDH	252		$\leq 300$
Cholesterol (mmol/L)	3.48		$\leq 5.20$
Triglycerides (mmol/L)	1.44		$\leq 1.70$
HDL (mmol/L)	0.48		$\geq 1.30$
LDL (mmol/L)	2.35		—
ESR (mm/h)	5		0-20
CRP (mg/L)	$<0.6$		$\leq 5.0$
TSH (mIU/L)	3.74		0.60-4.48
$\beta$ -glucocerebrosidase (nmol/h/mg)	0.6		5.0-11.3
Chitotriosidase (nmol/h/mL)	398	443	6-121

Abbreviations: ERT, enzyme replacement therapy; LKC, leukocyte count; Hg, hemoglobin; Plt, platelet; UBIC, unsaturated iron binding capacity; INR, international normalized ratio; PTT, partial thromboplastin time; ALT, alanine aminotransferase; AST, aspartate aminotransferase; ALP, alkaline phosphatase; GGT,  $\gamma$ -glutamyl transferase; LDH, lactate dehydrogenase; HDL, high-density lipoprotein; LDL, low-density lipoprotein; ESR, erythrocyte sedimentation rate; CRP, C-reactive protein; TSH, thyroid stimulating hormone.

ultrasound demonstrated resolved hepatosplenomegaly with improved liver enzymes and thrombocytopenia (Table 1).

## Discussion

Type 1 GD was first described in a doctoral thesis by Philippe Gaucher (1882) as a nonleukemic splenic epithelioma.<sup>4</sup> It is a rare condition with an estimated prevalence of 1 in 50 000 to 100 000 in the general population.<sup>5</sup> GD affects all ethnic and racial groups, through the prevalence is higher among those of Ashkenazi Jewish descent. The age of diagnosis is highly variable and typically correlates to the rate of substrate accumulation.<sup>5</sup> However, it is estimated that 66% of patients with GD Type 1 are diagnosed before 20 years of age.<sup>6</sup>

In a longitudinal observational study, the most common signs and symptoms of GD in children included splenomegaly (95%), hepatomegaly (87%), bone disease (81%), thrombocytopenia (50%), anemia (40%), growth retardation (34%), and bone pain (27%).<sup>7</sup>

Specifically, the 2 most common radiographic bone abnormalities in pediatric patients were Erlenmeyer flask deformities (49%) and bone marrow infiltration (38%).<sup>7</sup> Correspondingly, our patient was initially referred for hepatosplenomegaly and, after further investigation, was found to have concomitant thrombocytopenia and bilateral Erlenmeyer flask deformities of the femurs.

GD is diagnosed by measuring  $\beta$ -glucocerebrosidase activity in peripheral blood leukocytes. A finding of  $<15\%$  of mean normal activity is supportive of the diagnosis.<sup>8</sup> Our patient had a reduced serum level of 0.6 nmol/h/mg (5.0-11.3 nmol/h/mg), which was diagnostic of GD Type 1. Her serum chitotriosidase, a marker expressed by chronically activated phagocytes and released by glucocerebroside-laden macrophages, was elevated at 398 nmol/h/mL (6.0-121 nmol/h/mL), further supporting a diagnosis of GD.<sup>8</sup>

Molecular genetic testing confirms the diagnosis of GD and may provide valuable prognostic information. More than 300 variants of the GBA gene encoding for

glucocerebrosidase have been associated with GD, with the most common being c.1226A>G p.N409S (N370S), c.84dupG p.L29fs (84GG), c.115+1G>A (IVS2+1G>A), and c.1448T>C p.L483P (L444P).<sup>9</sup> Genetic testing revealed that one of the patient's mutations was the c.1226A>G (p.N409S) variant. This mutation is associated only with GD Type 1 and is thought to be protective against the development of the neurological involvement characteristic of GD Types 2 and 3.<sup>9</sup>

ERT is the first-line treatment for GD Type 1 in pediatric patients.<sup>10</sup> ERT replaces the defective acid  $\beta$ -glucosidase and enables the catabolism of glucocerebroside, which accumulates in macrophages, into glucose and ceramide.<sup>10,11</sup> Imiglucerase (Cerezyme) is most commonly used, though velaglucerase alfa (VPRIV) and taliglucerase alfa (Eyelyso) are also now approved for ERT in GD Type 1. The dose can range from 15 to 60 U/kg biweekly based on the clinical severity and response. There is reported improvement in hematological, visceral, and bone parameters within 6 months of therapy.<sup>12</sup> Other therapies include substrate reduction medications, bone marrow transplantation (used in some cases of types 2 and 3), splenectomy (no longer recommended), and potential gene therapies (currently being investigated in clinical trials).

Our patient was treated intravenously with 60 U/kg of imiglucerase (Cerezyme) biweekly. Her thrombocytopenia subsequently resolved with a platelet count of  $170 \times 10^9/L$  after 6 months and  $172 \times 10^9/L$  after 2 years of treatment. This is consistent with Weinreb et al's study, where 54% of patients with initial platelet counts of  $60$  to  $120 \times 10^9/L$  reached normal levels after 24 months of ERT.<sup>13</sup> In this study, hemoglobin concentrations in anemic patients also increased to normal or near normal levels within 6 to 12 months.<sup>13</sup>

Remarkably, at 2 years following initiation of ERT, our patient's hepatosplenomegaly was undetectable by both clinical examination and ultrasound. This is also reflected in the literature, where liver volumes were found to decrease by 20% to 30% at 1 to 2 years, and 30% to 40% by 5 years of treatment. Splenic volumes similarly decreased by 30% within 1 year of therapy, and 50% after 2 years.<sup>13</sup> Finally, in patients with pre-treatment bone pain, 52% were pain free after 2 years.<sup>13</sup> Although our patient still endorsed bony pain at a 2-year follow-up, this was clinically improved from initial assessment. A repeat magnetic resonance imaging 6 months following ERT initiation showed persistent mild Erlenmeyer flask deformities, but without bone infarcts.

A multidisciplinary approach is essential in the long-term management of GD Type 1. In addition to

facilitating and observing response to ERT, medical specialists must monitor for long-term complications. In GD Type 1, aberrant macrophage activation and immune dysregulation are associated with an increased risk of cancer in the site of the metabolic disease and in secondary organs involved in the disease process.<sup>14</sup> Additionally, due to mutations in the *GBA* gene, it has been found that Parkinson disease may develop in 4% to 9% of GD Type 1 patients.<sup>15</sup> Long-term management should also encompass genetic counselling, as GD is inherited in an autosomal recessive manner. Last, allied health care professionals are vital in managing subsequent psychosocial aspects of care.

In summary, GD is a rare, but important, treatable diagnosis in pediatric patients presenting with hepatosplenomegaly. Associated hematological abnormalities including thrombocytopenia and anemia, and skeletal manifestations should raise clinical suspicion for GD. Measuring glucocerebrosidase activity in dried blood spots is a reliable and cost-effective method to diagnose GD early in individuals with hepatosplenomegaly and/or thrombocytopenia. Diagnosis is supported by a high serum chitotriosidase and genetic testing, with c.1226A>G being the most common deletion mutation seen in GD Type 1. Biweekly enzyme replacement therapy with imiglucerase has been proven to improve hematological, visceral, and bony manifestations of the disease. Physicians must consider the rare diagnosis of GD in patients presenting with hepatosplenomegaly to prompt early diagnosis and timely management.

### Acknowledgments

We thank the patient and her family for allowing us to share her information.

### Author Contributions

HCB: Contributed to conception and design; contributed to analysis; drafted the manuscript; gave final approval; agrees to be accountable for all aspects of work ensuring integrity and accuracy.

CP: Contributed to analysis and interpretation; critically revised the manuscript; gave final approval; agrees to be accountable for all aspects of work ensuring integrity and accuracy.

CAP: Contributed to analysis and interpretation; critically revised the manuscript; gave final approval; agrees to be accountable for all aspects of work ensuring integrity and accuracy.

DA: Contributed to analysis and interpretation; critically revised the manuscript; gave final approval; agrees to be accountable for all aspects of work ensuring integrity and accuracy.

## Declaration of Conflicting Interests

The author(s) declared no potential conflicts of interest with respect to the research, authorship, and/or publication of this article.

## Funding

The author(s) received no financial support for the research, authorship, and/or publication of this article.

## ORCID iD

Hailey C. Barootes  <https://orcid.org/0000-0003-4175-9315>

## References

1. Jmoudiak M, Futerman AH. Gaucher disease: pathological mechanisms and modern management. *Br J Haematol*. 2005;129:178-188.
2. Stirnemann J, Belmatoug N, Camou F, et al. A review of Gaucher disease pathophysiology, clinical presentation and treatments. *Int J Mol Sci*. 2017;18:441.
3. Shawky RM, Elsayed SM. Treatment options for patients with Gaucher disease. *Egypt J Med Hum Genet*. 2016;17:281-285.
4. Goldblatt J. Type I Gaucher disease. *J Med Genet*. 1988;25:415-418.
5. Cox TM, Schofield JP. Gaucher's disease: clinical features and natural history. *Baillieres Clin Hematol*. 1997;10:657-689.
6. Grabowski GA, Andria G, Baldellou A, et al. Pediatric non-neuronopathic Gaucher disease: presentation, diagnosis and assessment. Consensus statements. *Eur J Pediatr*. 2004;163:58-66.
7. Kaplan P, Andersson HC, Kacena KA, Yee JD. The clinical and demographic characteristics of nonneuronopathic Gaucher disease in 887 children at diagnosis. *Arch Pediatr Adolesc Med*. 2006;160:603-608.
8. Aerts JMFG, Kallemeijn WW, Wegdam W, et al. Biomarkers in the diagnosis of lysosomal storage disorders: proteins, lipids, and inhibitors. *J Inher Metab Dis*. 2011;34:605-619.
9. Smith L, Mullin S, Schapira AHV. Insights into the structural biology of Gaucher disease. *Exp Neurol*. 2017;298 (pt B):180-190.
10. Cox T, Lachmann R, Hollak C, et al. Novel oral treatment of Gaucher's disease with N-butyldeoxynojirimycin (OGT 918) to decrease substrate biosynthesis. *Lancet*. 2000;355:1481-1485.
11. Cox TM, Amato D, Hollak CE, et al. Evaluation of miglustat as maintenance therapy after enzyme therapy in adults with stable type 1 Gaucher disease: a prospective, open-label non-inferiority study. *Orphanet J Rare Dis*. 2012;7:102.
12. Serratrice C, Carballo S, Serratrice J, Stirnemann J. Imiglucerase in the management of Gaucher disease type 1: an evidence-based review of its place in therapy. *Core Evid*. 2016;11:37-47.
13. Weinreb NJ, Charrow J, Andersson HC, et al. Effectiveness of enzyme replacement therapy in 1028 patients with type 1 Gaucher disease after 2 to 5 years of treatment: a report from the Gaucher Registry. *Am J Med*. 2002;113:112-119.
14. Mistry PK, Taddei T, vom Dahl S, Rosenbloom BE. Gaucher disease and malignancy: a model for cancer pathogenesis in an inborn error of metabolism. *Crit Rev Oncog*. 2013;18:235-246.
15. Alcalay RN, Dinur T, Quinn T, et al. Comparison of Parkinson risk in Ashkenazi Jewish patients with Gaucher disease and GBA heterozygotes. *JAMA Neurol*. 2014;71:752-757.