Spring April 30, 2009

The anatomical role of Scarpa's fascia in the manifestation of clinical signs associated with retroperitoneal haemorrhage and bile leakage

Shahnoor Ullah, *University of Western Ontario*

The anatomical role of Scarpa's fascia in the manifestation of clinical signs associated with retroperitoneal haemorrhage and bile leakage.

Scarpa's fascia: Retroperitoneal Haemorrhaging and Bile Leak

Monograph

by

Shahnoor M. Ullah B.M.Sc., M.Sc.

Graduate Program in Anatomy and Cell Biology

A thesis submitted in partial fulfillment
of the requirements for the degree of
Master of Science

The School of Graduate and Postdoctoral Studies
The University of Western Ontario
London, Ontario, Canada

- Abstract -

While the aetiology of eponymous surface signs of retroperitoneal haemorrhage and bile leakage is known, it is unclear what causes their appearance. The location of Scarpa's fascia makes it a potential candidate in understanding the pattern of these signs. In this study, dissections were performed on seven embalmed cadavers and the Visible Human Project was examined to determine Scarpa's fasica's role in these clinical signs. Scarpa's fascia attaches where the umbilicus emerges from the external oblique aponeurosis providing a deficiency that may cause the bruising in Cullen's sign. As the membranous layer continues into the flanks, it creates a pocket which may account for Turner's sign. The continuation of the membranous layer into the axilla and chest forms another pocket where bile may accumulate in *Icterus Marginatus*. The anatomical characteristics of Scarpa's fascia described by this study suggest that it plays a role in the development of these clinical signs.

- Keywords -

Scarpa's fascia, membranous layer, Scarpa's, membranous, membranous layer of superficial fascia, superficial fascia, retroperitoneal hemorrhaging, retroperitoneal haemorrhaging, retroperitoneal bile leakage, retroperitoneal bile leak, Cullen's sign, Turner's sign, icterus marginatus, clinical signs, pancreatitis, laparoscopic cholecystectomy, jaundice, bile

Antonio Scarpa 1752-1832

anatomist, physician and educator

2009 marks the two hundred year anniversary since Antonio Scarpa first described the membranous layer of superficial fascia, Scarpa's fascia.

- to my mother, father, brother and sister -

and

- to the donors for their noble and selfless gift for the sake of education and research. Thank you for giving me this wonderful opportunity to learn –

- in honour of my grandfather, nana and khalu -

- Acknowledgements -

I would like to thank Dr. Vivian McAlister for supervising my project and having faith in me. Without his creativity, insight and leadership, none of this would have been possible.

Robert Grant, his assistance has made the challenge of conducting the dissections easier and enjoyable.

Dr. Marjorie Johnson and Dr. Peter Haase for their time and contribution to my thesis.

Dr. Khadry Galil, Dr. Walter Rushlow and Dr. Timothy Wilson, my remaining supervisory committee members for their guidance.

Haley Linklater, Gross Anatomy Laboratory Supervisor, for all the laboratory support, equipment and logistics.

Department of Anatomy and Cell Biology, Schulich School of Medicine and Dentistry, the University of Western Ontario for allowing me access to the cadavers and Anatomy Laboratory facilities.

Corps for Research of Instructional and Perceptual Technologies (CRIPT) for granting me access to the Visible Human Project.

Dr. John Kiernan for his expertise and assisting me in developing the Sudan black mineral oil solution for my research.

Kayla Sheppard for her support throughout this entire process.

Michael Midgley with whom I've attended high school, university and graduate school.

Clinical Anatomy Class of 2009 (Sarah B, Katie B, Robin H, Christina L, Mike M, Aimee S, Tamara S, Marcus V, Mike W and Harold Y) for all the memories.

And finally, I thank God for all the opportunities that he has presented me and for all his blessings. Without him none of this would ever be possible nor would it matter.

- Table of Contents -

- Table of Contents -

- List of Figures -

Introduction

Materials and Methods

Materials and Methods

1.1 Background

In the clinical setting, a physician has two empirical resources in assisting the patient. These are the patient's signs and symptoms. There is an important

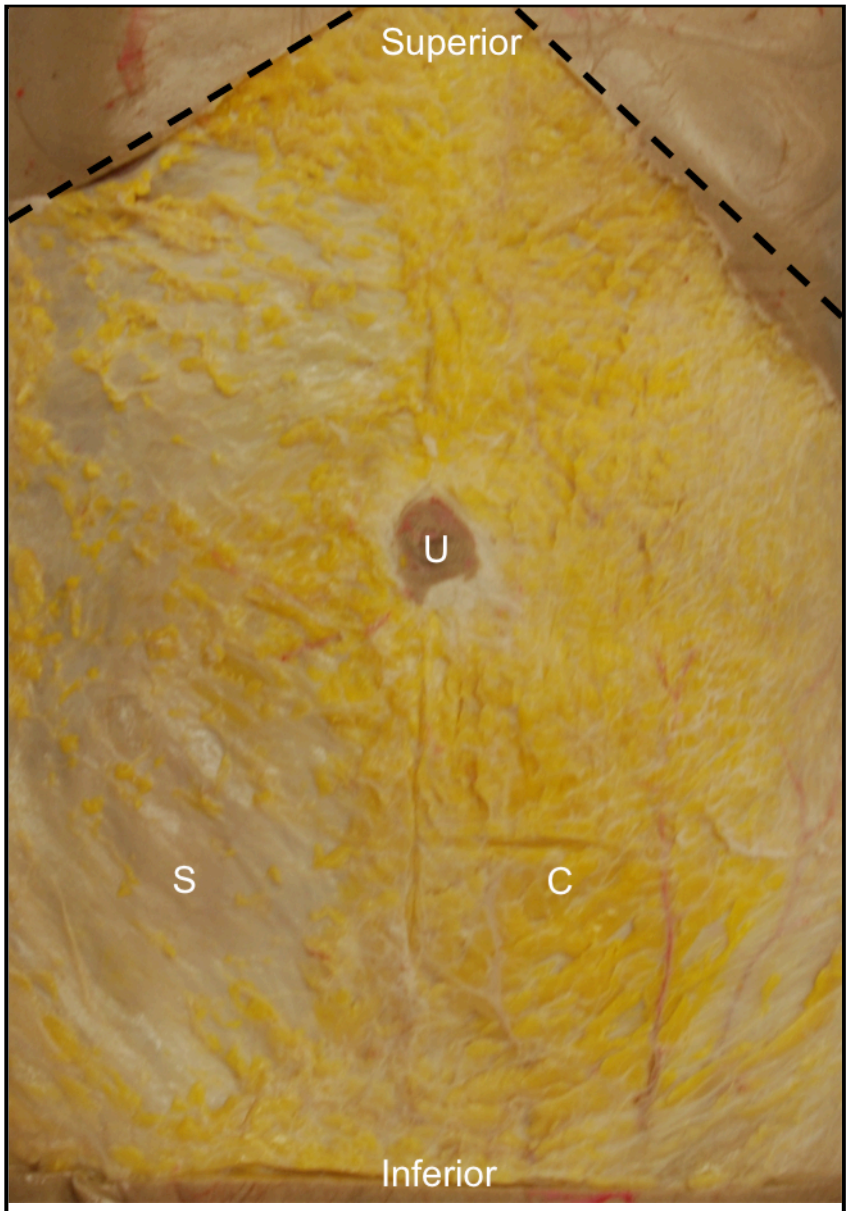

Figure 1-1. Scarpa's fascia, the deep membranous layer of superficial fascia. *(Dashed lines) Costal margin, (U) Umbilicus, (S) Scarpa's fascia, (C) Camper's fascia*

distinguishing feature between what a sign is and what a symptom is. A symptom is the subjective experiences felt by the patient, which the patient can describe to his/her physician. On the other hand, a medical sign is an objective indication of the physical state of a patient detected by the physician during a physical examination. Thus, due to the objective nature of medical signs, it provides a valuable asset to physicians in assisting in the diagnosis of the patient's condition. Medical signs can manifest anywhere in the body, and often where it does show up or how it shows up is anatomically tied and a clue to the condition causing the sign[1].

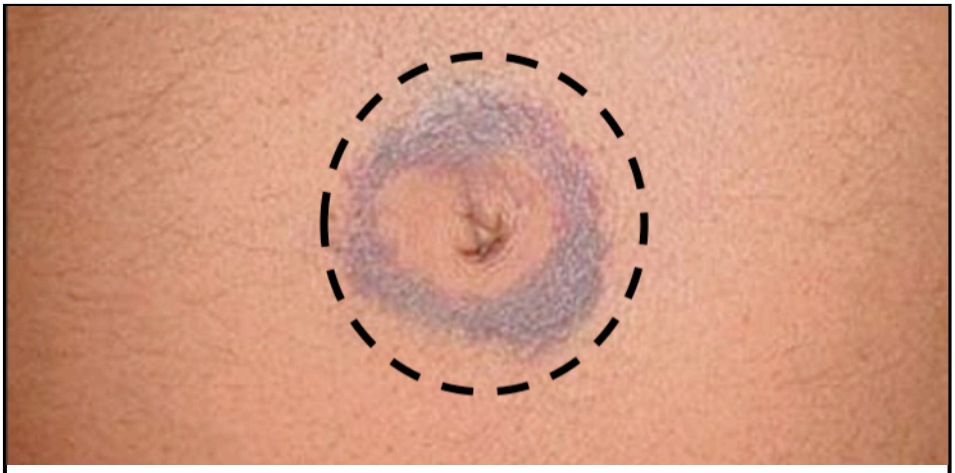

Figure 1-2. Cullen's sign. Bruising around the umbilicus is seen due to retroperitoneal hemorrhaging. *Image Source: Chauhan S et al.*

One particular area where medical signs play a very important role is in the area of the abdomen, specifically in relation to Scarpa's fascia (will be used interchangeably with the term "membranous layer")[2,3]. Scarpa's fascia is the deep membranous layer of the superficial fascia found in the abdomen[4,5,6](figure 1-1).

In 1918, Dr. Thomas Cullen reported bruising around the area of the umbilicus in one of his patients (figure 1-2). This was due to a ruptured ectopic pregnancy, causing intraabdominal hemorrhage, which manifested in the umbilicus (Cullen's sign) [7]. Just a couple of years later, British surgeon, Dr. Grey Turner described bruising of the loins (figure 1-3) as well as the umbilicus also due to intraabdominal hemorrhage (Turner's sign) [8]. In 1966, Dr. J A Fox described two cases where bruising was noted in upper parts of the thigh with a definitive upper margin. He associated Scarpa's fascia with this upper border, since it correlated to Scarpa's fascia's inferior attachment to the fascia lata of the thigh (Fox's sign) [5]. In 1984, a case was reported regarding bile staining in the right flank as well as in the scrotum. Bile staining in the right flank was compared to its similarity in Tuner's sign[9]. In 1987, a group of physicians described ecchymosis of the penile shaft and left scrotum, attributing this to an early abdominal aortic aneurysm. This sign was described as the blue scrotum sign of Bryant after John Henry

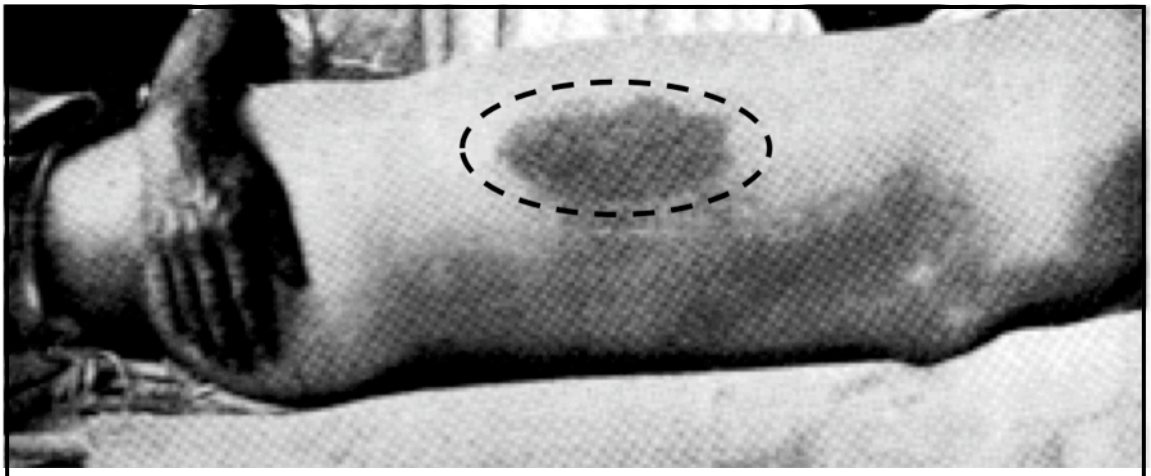

Figure 1-3. Turner's sign. Oval shaped bruising in the flanks due to retroperitoneal hemorrhaging. *Image Source: Turner G et al.*

Bryant an influential physician for Guy's Hospital from 1886-1906 (Bryant's sign)[10].

This study was inspired by a previously presented case report by McAlister et al describing a 59 year old male patient 5 days after undergoing a laparoscopic cholecystectomy. Laparoscopic cholecystectomy is a surgical procedure where the gall bladder is removed via small incisions in the abdomen using a laparoscope[43]. The patient presented with jaundice and a swollen penis. The jaundice was presented in the torso, perineum and upper thigh, and was markedly contrasted from the sclera, face and arms, which appeared normal. The jaundice was limited superiorly 3 cm below the clavicle and inferiorly 3 cm below the groin skin crease[3]. This representation of jaundice in this region was very similar to areas described in Turner's sign and Fox's sign. McAlister et al dubbed this sign, "icterus marginatus", referring to the pattern of bile staining seen in the lateral chest wall, flank and perineum (figure 1-4).

While the causes of the above signs are known [retroperitoneal bile leakage or hemorrhaging], it is unclear why the different signs have their characteristic physical appearances such as the bruising around the umbilicus seen in Cullen's sign. The close proximity of Scarpa's fascia with these clinical signs allows it to be an excellent candidate responsible for the structural role in their physical manifestation. It is already well known that Scarpa's fascia plays a structural role in the development of Fox's sign. Dr. Fox attributed the upper limits of bruising to the inferior attachment of Scarpa's fascia with the fascia lata of the thigh[2].

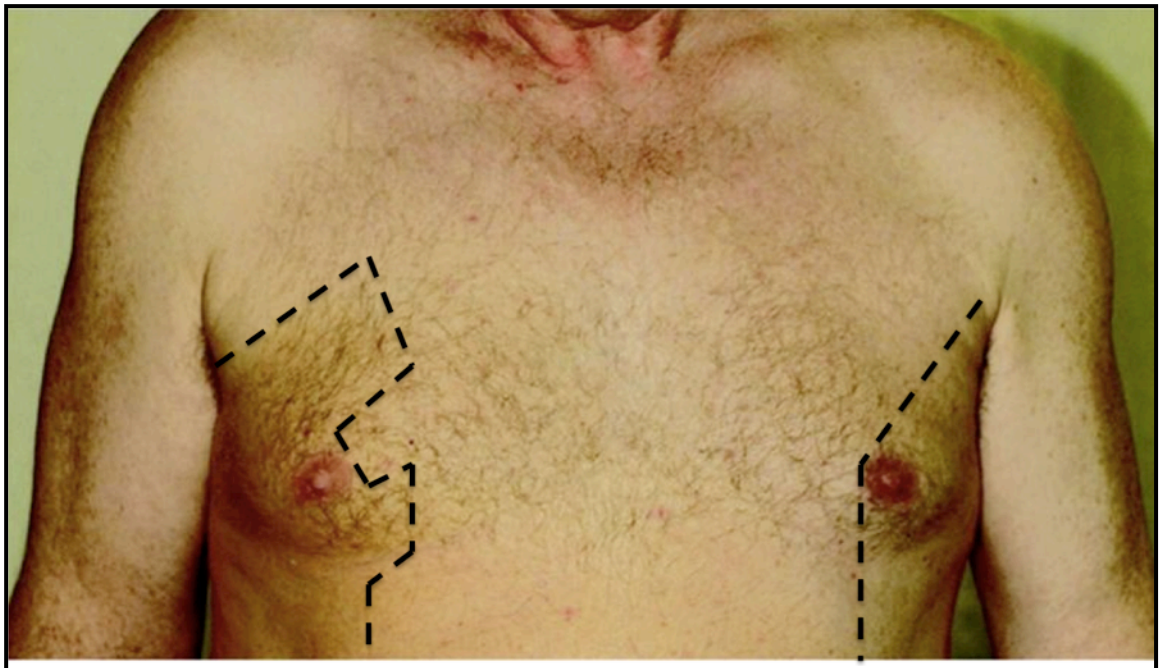

Figure 1-4. Icterus marginatus. Jaundice of the lateral chest walls, torso and perineum and a swollen penis due to retroperitoneal bile leakage. *Image Source: McAlister V et al.*

Scarpa's fascia was first described by Antonio Scarpa in 1809[5]. Since then, the study of Scarpa's fascia has been primarily focused on its attachments inferiorly and laterally[4,27]. Inferiorly, Scarpa's fascia is continuous with Colle's fascia of the perineum. Infero-laterally, Scarpa's fascia attaches to the fascia lata of the thigh. The lateral and superior borders of Scarpa's fascia however, are currently ill-defined in the literature (figure 1-5).

While the inferior and infero-lateral attachments of Scarpa's fascia sheds light into Fox's sign and Bryant's sign, the uncertainty of its superior and lateral borders poses an obstacle for its association with the remaining signs. In this study, we investigated Scarpa's fascia's implications with respect to Cullen's sign, Turner's sign and icterus marginatus. Since Thomas Cullen described the peri-

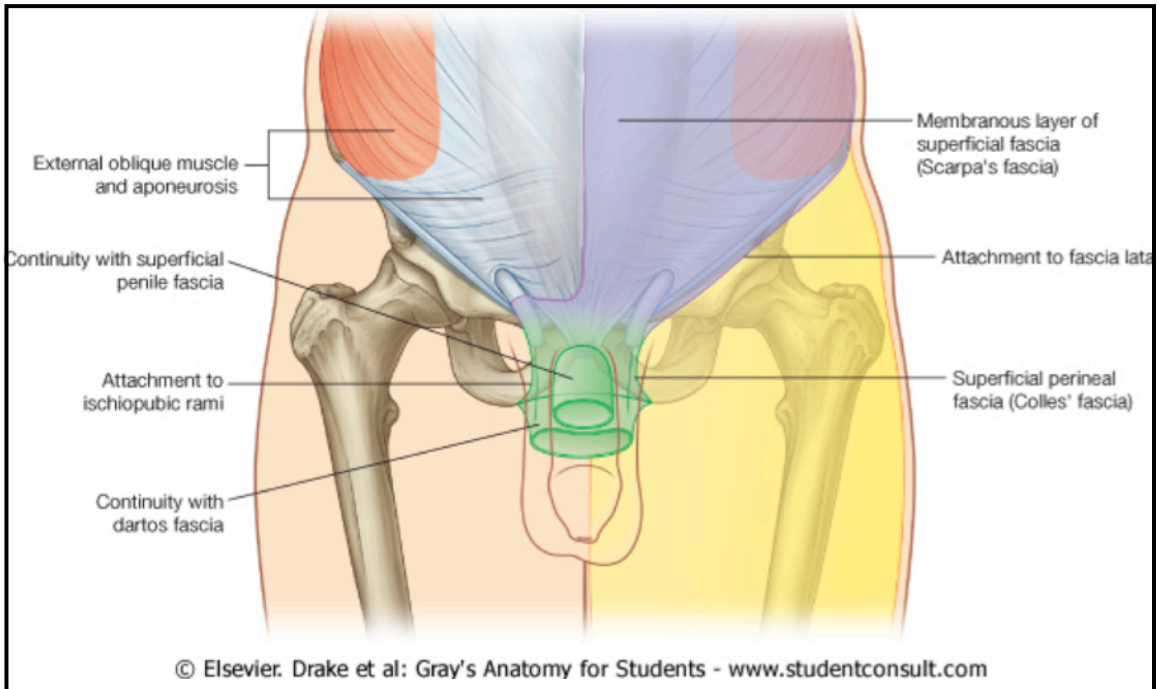

Figure 1-5. Scarpa's fascia (purple). In current literature and textbooks Scarpa's fascia is defined as a membranous layer of superficial fascia in the abdomen. It continues inferiorly as Colle's fascia and attaches infero-laterally to fascia lata. *Image Source: Drake et al.*

umbilicial discoloration, Cullen's sign has been attributed to causes other than pancreatitis. It is also seen in perforated duodenal ulcer[11], metastatic esophageal carcinoma[12], splenic rupture secondary to infectious mononucleosis[13], ovarian enlargement secondary to primary hypothyroidism[14], amoebic liver abscess[15], portal hypertension[16], hepatoma[17] and rectus sheath hematoma[18]. Thus it has been suggested that Cullen's sign should be seen as a sign of retroperitoneal bleeding instead of a definitive sign of pancreatitis[18]. Turner's sign on the other hand, hasn't been attributed to as many different causes as Cullen's, but it has been implicated in hepatocellular carcinoma[19], portal hypertension[16] and retroperitoneal bile leaks[9].

Retroperitoneal bile leaks have been reported multiple times in the literature. Whipple first described a bile cyst in the peritoneal cavity[20]. Later, Gould and Patel coined the term "biloma". Biloma, is a collection of bile fluid which is encapsulated[21]. Colovic then coined the term "retroperitoneal biloma" to describe bile accumulation in the retroperitoneum[22]. Retroperitoneal biloma has been primarily attributed to common bile duct injury[9,22], however it has also been described in rare instances in choledocolithiasis[23], spontaneous rupture of the bile duct[24] and spontaneous rupture of a biliary diverticulum within the distal common bile duct[25]. There has also been a case where bile leaked into the thoracic cavity[26].

A recent paper demonstrated that in fact the membranous layer of superficial fascia exists throughout the body and is not just confined to the abdomen and the perineum[28]. This leads to the possibility that the pockets created by Scarpa's fascia in the abdomen can exist elsewhere in the body as well. With respect to Cullen's sign, it is possible that the bruising around the umbilicus is actually due to Scarpa's fascia's attachment to the umbilicus. Scarpa's fascia creates two oval pockets in the abdomen that continue into the perineum[4]. With evidence for the membranous layer being present in the flanks[28], the area of bruising for Turner's sign, it is possible that a similar pocket exists in this region that can give rise to the pattern seen in Turner's sign. Finally, with respect to icterus marginatus, another pocket may exist in the axilla and chest to explain the bilateral jaundice seen in the chest wall.

1.2 Purpose

The purpose of this study was to investigate Scarpa's fascia's limits and attachments and determine whether it plays a role in the development of clinical signs associated with retroperitoneal hemorrhaging and bile leakage.

1.3 Objectives

To assess the distribution of Scarpa's fascia and its implication with clinical signs of retroperitoneal hemorrhaging and bile leakage, the following objectives were set:

1. Exploratory Dissections on 4 embalmed cadavers: The primary purpose of this was to establish a standard method for dissecting Scarpa's fascia.
2. Dissections on 7 embalmed cadavers to assess Scarpa's fascia's attachments and limits and to relate the findings to the locations where the clinical signs present (ie. investigating the flanks for Turner's sign).
3. Administration of Sudan black mineral oil solution, as a means to establish the limits of the pockets created by Scarpa's fascia and whether the membranous layer was impermeable to fluid.
4. Analysis of the female and male data sets from the Visible Human Project. The Visible Human Project consists of transverse images of a frozen cadaver (cryosections). These frozen cadavers were sliced in 0.33 mm and 1 mm for the female and male respectively. As a result, each cross sectional image was very detailed[42]. Due to the high resolution of the

cryosections; the skin, Camper's fascia and Scarpa's fascia can be clearly differentiated (refer to figure 2-6 in materials and methods). Therefore, the data sets were used to gain an additional perspective in assessing Scarpa's fascia and its limits.

2.1 Source of Cadavers

Cadavers were provided by the Department of Anatomy and Cell Biology and Schulich School of Medicine and Dentistry at the University of Western Ontario. These cadavers were later used by medical students for anatomical dissections.

2.2 Selection of Cadavers

A total of eleven embalmed cadavers were used in this study. Four embalmed cadavers were used to practice dissecting Scarpa's fascia and to establish a protocol for the dissections. The seven remaining cadavers were used for the dissections related to the three clinical signs and was analyzed and reported in our results.

The seven embalmed cadavers selected ranged in age from 60 to 92 (average age 76). Of the seven, three were male and four were female. Specific details of each cadaver and their cause of death are listed in table 2-1. Cadavers were selected on the basis of having normal abdominal surface anatomy. Therefore, cadavers with abdominal procedures such as colostomy and gastrostomy were omitted. No cadavers from this study were excluded as the seven cadavers that were randomly picked had normal abdominal surface anatomy. Scarpa's fascia was investigated with respect to the following three signs: Cullen's, Turner's and icterus marginatus. Each sign had its own dissection approach.

Subject	Age	Sex	Cause of Death
1	F	88	Acute Myocardial Infarction, Arteriosclerotic Heart Disease
2	F	92	Acute Leukemia, Advanced Age
3	F	72	Hepatic Carcinoma
4	M	63	Metastatic Tonsillar Cancer
5	F	60	Neuroendocrine CA with extensive liver mets; primary unknown
6	M	84	Metastatic Renal Cell Carcinoma
7	M	87	Metastatic Bladder Cancer

Table 2-1. List of cadavers used for dissections. All subjects had normal surface anatomy. There was no evidence of any surgical intervention that may have altered the underlying fascia.

With respect to icterus marginatus, only the male cadavers were examined. There were several reasons for this. First, the case describing icterus marginatus occurred in a male patient. Second, the fascia system is different in the female axilla and chest due to the mammary glands[42]. Third, time was limited for dissections as the cadavers were utilized by medical students for anatomical education. Therefore, in order to keep the dissections relevant to icterus marginatus, studies were focused on the male cadaver for this clinical sign. It should be noted however, that with respect to Cullen's sign and Turner's sign, no such discrimination was made.

2.3 Embalming Process

Cadavers were embalmed 48 hours post-mortem. 24-32 litres of UWO embalming solution was injected retrogradely through the right femoral artery and left common carotid artery. This process took about 30 minutes. The UWO embalming solution consisted of 50% ethyl alcohol, 25% propylene glycol, 16% water, 3.5% formaldehyde, 2% dettol, 2% phenol and 1.5% sodium acetate. Once embalmed the cadavers were stored in the cooler. 2-3 days later they were re-injected with an additional 4-8 litres of UWO embalming solution. They were stored in the cooler once again. Once the embalming fluid had been absorbed by the bodily tissues, 650 mL of diluted latex was injected into the cadaver.

(Acknowledgement: Haley Linklater)

2.4 Documentation

All dissections were documented by digital photography using the Nikon D80 SLR camera. Dissections were photographed under 3872 x 2592 resolution.

(Acknowledgement: Department of Anatomy and Cell Biology, University of Western Ontario)

2.5 Dissections

Exploratory Dissections of Scarpa's Fascia (n=4)

Initial dissections were performed on 4 cadavers as a means to gain experience and practice. Different methods were employed to assess the best approach to

dissect Scarpa's fascia. The purpose of this exercise was solely for experience and as such no results were collected from these dissections.

To maintain the structural integrity of the membranous layer and Scarpa's fascia, the following approach was adopted. Only the skin was reflected, leaving the underlying fatty layer [hypodermis] intact. The fatty layer was then removed by elevating the fat with forceps and releasing its adhesions with a scalpel. This assured that only the skin and the superficial fascia was removed while leaving the membranous layer intact (figure 2-1). This method was supervised by Dr. Vivian McAlister M.B., who is a general surgeon for the Multi-Organ Transplant Program in the Department of Surgery, University Hospital, Schulich School of Medicine and Dentistry at the University of Western Ontario.

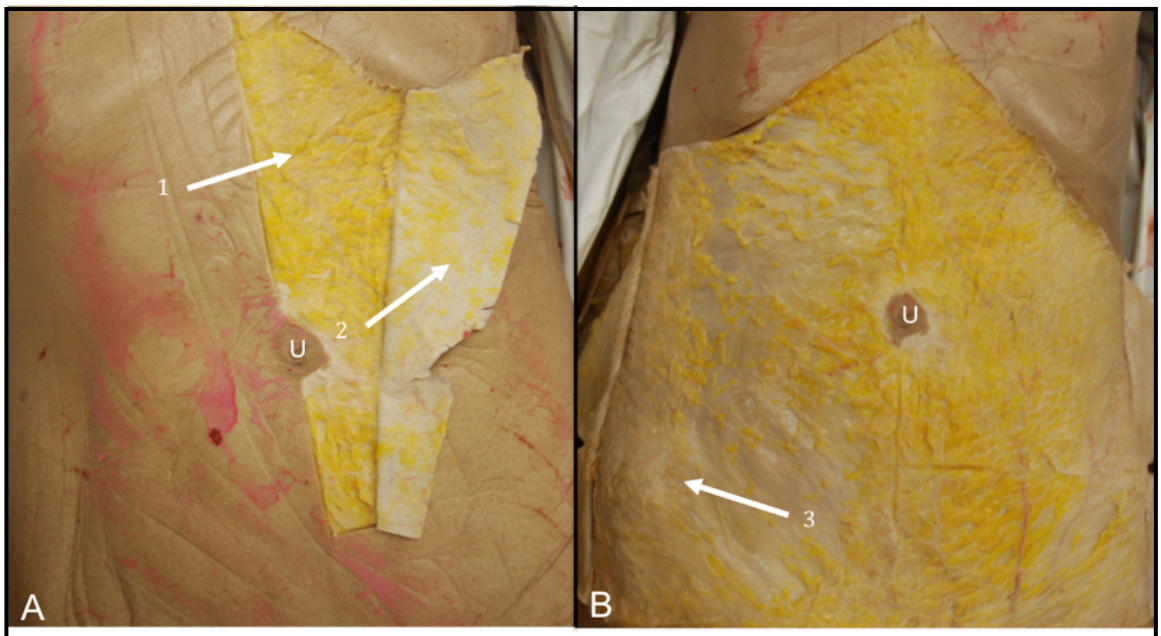

Figure 2-1. Demonstration of the dissection approach to reach Scarpa's fascia. A. (1) As the skin is reflected, the underlying fatty layer (Camper's fascia) is left intact. The yellow fascia seen is Camper's fascia. B. (2) Only the skin is reflected back as there is virtually no Camper's fascia adherent to the skin. (3) As Camper's fascia is removed, the underlying membranous layer is revealed. *(U) Umbilicus*.

The Demonstration of a Continuous Membranous Layer (n=1)

A midline incision was performed from the manubrium to the pubic region. The skin was reflected laterally on both sides to the extent that the lateral sides of the trunk were exposed. The underlying fatty layer was left intact (figure 2-2). The fatty layer was removed by elevating the fat using forceps and then releasing its

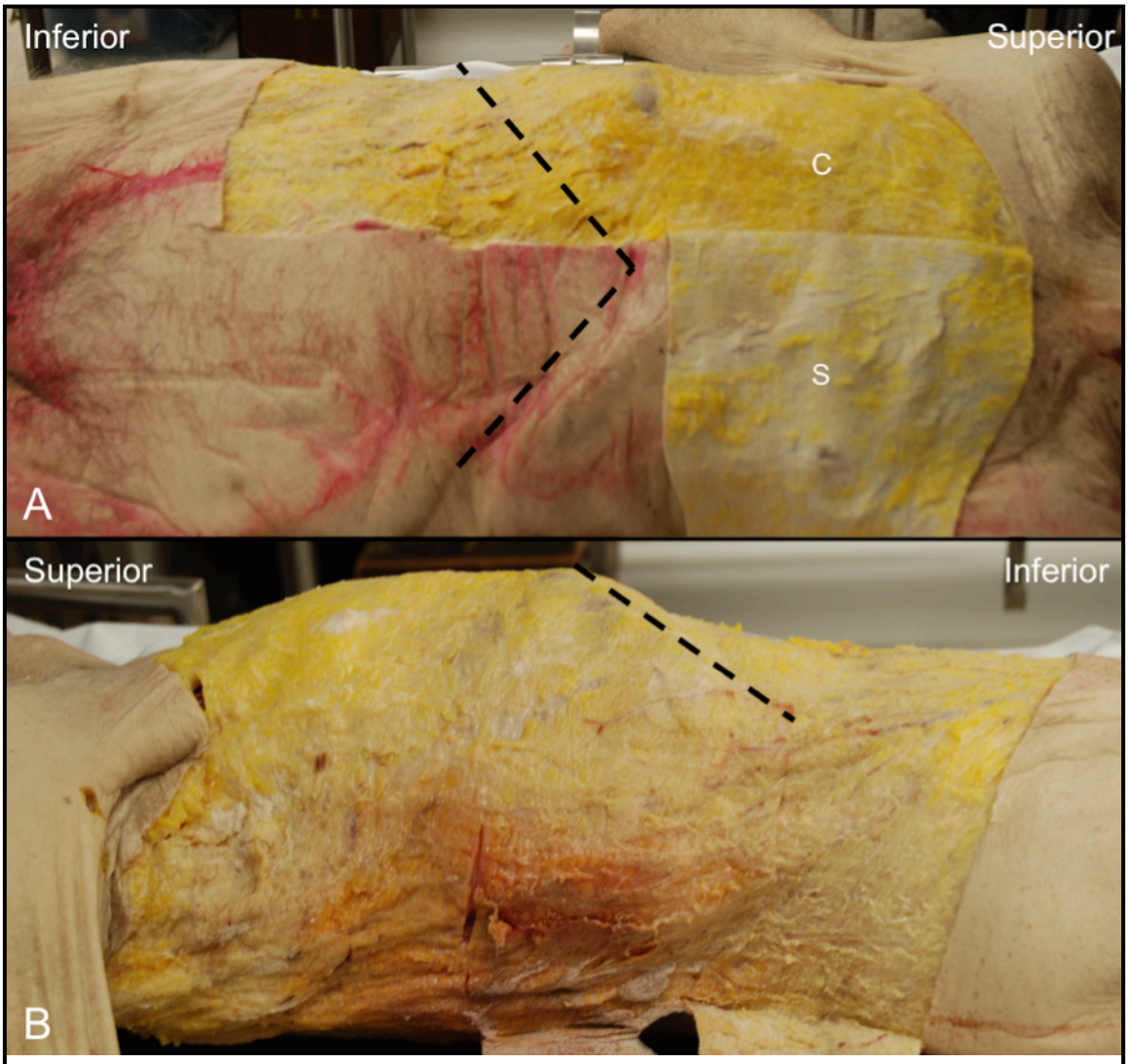

Figure 2-2. Demonstration of reflection of skin from chest and abdomen from the midline to the extent such that the lateral side of the trunk was exposed. Note that the underlying Camper's fascia was left intact. (A) Anterior view of the cadaver. (B) Lateral view of the cadaver. *(Dashed Lines) Costal Margin, (S) Skin reflected. (C) Camper's fascia.*

adhesions with a scalpel. Starting at the abdomen, Scarpa's fascia was identified. To confirm that this was indeed Scarpa's fascia, analysis of the different layers in the abdomen was performed. When making an incision in the abdomen from superficial to deep, one will encounter in order: skin, Camper's fascia, Scarpa's fascia, external oblique aponeurosis and then the anterior abdominal wall muscles[41]. As figure 2-3 demonstrates, an incision was made to showcase all these different layers in order. This confirmed the identification of the membranous layer as Scarpa's fascia.

Figure 2-3. Demonstration of the different layers seen when performing an abdominal incision. Yellow remnants are remainders of Camper's fascia. *(U) Umbilicus, (R) Rectus abdominus, (E) External oblique aponeurosis, (S) Scarpa's fascia, (C) Camper's fascia*

Starting below the umbilicus, Scarpa's fascia was reflected superiorly to assess the continuation of this membranous layer. It was dissected up to the level of the clavicle and then reflected laterally to expose the axilla and lateral sides of the body wall. This demonstrated the existence of the membranous layer in the chest, axilla, lateral sides and the abdomen.

Cullen's Sign (n=4)

The target for this sign was the umbilicus. Therefore a mid-line abdominal incision was performed from the xyphoid process straight down to the pubic region. Skin was reflected laterally from the mid-line, leaving the underlying Camper's fascia intact. This was done on both sides of the abdomen. Camper's fascia was then removed by elevating the fascia with forceps, and releasing the fat from its underlying adhesion with a scalpel. Once this was removed, the appearance of the membranous layer was checked. Incisions were made several inches below the umbilicus into the membranous layer. The membranous layer was then separated from the underlying external oblique aponeurosis using a blunt probe. The membranous layer was opened via blunt dissection using a blunt probe. Once the blunt probe was no longer able to penetrate, the limits of the membranous layer were established.

Scarpa's fascia was then followed to the umbilicus where it was firmly attached. Scarpa's fascia's lateral borders were then released so that it was only attached to the umbilicus. This allowed for a closer observation of its attachment and distribution around the umbilicus.

Turner's Sign (n=4)

The target for this sign was the flanks, the area between the costal margin and the iliac crest on the lateral sides of the body. It is important to note that as these bodies were used by the medical school, the left side of the cadaver's back and lateral side were pre-dissected, so for Turner's sign only the right side of the cadaver was assessed. An incision was made from the midline of the back superiorly at the level of the costal margin and inferiorly to the level of the iliac crest. Skin was reflected all the way to the midline of the abdomen. The underlying fatty layer was left intact. This fatty layer was then removed using forceps to elevate the fat and then released with the use of a scalpel.

The cadaver was then tilted 45 degrees on its side so that its lateral side could be assessed (figure 2-4). Using a pair of forceps, the membranous layer was elevated looking for any loose attachments. Once a loose attachment was found, while the membranous layer remained elevated, an incision was made. Blunt dissection was performed with a blunt probe. Once the probe was no longer able to penetrate, the limits were established. Finally, the loose region of the membranous layer was then opened by making a vertical incision through it. The appearance of the membranous layer was noted as well as its attachments in the lateral side of the body.

Icterus Marginatus (n=3)

The target for this sign was the axilla and lateral chest wall. Once again, due to the

Figure 2-4. Demonstration of the cadaver tilted 45 degrees for assessment of Turner's sign and icterus marginatus. *(S) Skin reflected, (Dashed lines) Costal Margin.*

pre-dissections on the left side of the body, only the right side of the body was assessed. An incision was made along the midline of the back from the level of the axilla to the level of the iliac crest. The skin was then reflected to the anterior mid-line. The underlying fatty layer was left intact. This fatty layer was then removed using forceps to elevate the fat and then released with the use of a scalpel.

The cadaver was then tilted 45 degrees on its side so that the axilla as well as the chest wall could be assessed. With the use of forceps, the membranous layer was elevated to look for loose attachments. Once this was found an incision was made. Using blunt dissection the underlying region was opened. Once the blunt probe was no longer able to penetrate, the limits were established. Finally a vertical incision was made to open up this loose region and the membranous layer and its attachments were noted.

2.6 Staining

Preparation

0.15 g of Sudan black was added to 500 mL of 100% heavy mineral oil [0.3 g/L Sudan black mineral oil solution]. This solution was lipid soluble and as such did not stain the membranous layer itself. However, due to the dark color produced by Sudan black it was possible to see the solution through the membranous layer. *(Acknowledgement: Dr. John Kiernan, Department of Anatomy and Cell Biology, University of Western Ontario)*

Cullen's

0.3 g/L Sudan black mineral oil solution was inserted into the left side of the abdominal pocket formed by Scarpa's fascia in the abdomen with a pipette. The incisions were then sealed using haemostats. The stain was then assessed 24 hours later.

Turner's

0.3 g/L Sudan black mineral oil solution was inserted into the open pocket of the right flank formed by the membranous layer. With the cadaver on its back, the pocket was opened anteriorly while remaining intact posteriorly, superiorly and inferiorly. The containment of the solution in this pocket was assessed 24 hours later.

Icterus Marginatus

0.3 g/L Sudan black mineral oil solution was inserted into the loose region of the membranous layer in the abdomen with a pipette. The incisions were then sealed using haemostats. The cadaver remained tilted 45 degrees on its side such that the right side was facing up. The stain was then assessed 24 hours later.

2.7 Visible Human Project

Visible Human Project data sets for male and female cryosections were accessed from the Corps for Research of Instructional and Perceptual Technologies (CRIPT) in the Department of Anatomy and Cell Biology at the Schulich School of Medicine and Dentistry, the University of Western Ontario (London, Ontario, Canada). Permission was granted from the United States National Library of Medicine (NLM) to use the Visible Human Project for anatomical research.

The female cryosection data set was used for analysis for Cullen's sign and Turner's sign because this data set was of better quality compared to the male

cryosection data set. With respect to icterus marginatus, the male cryosection data set was examined since the fascia system is different in the axilla and chest

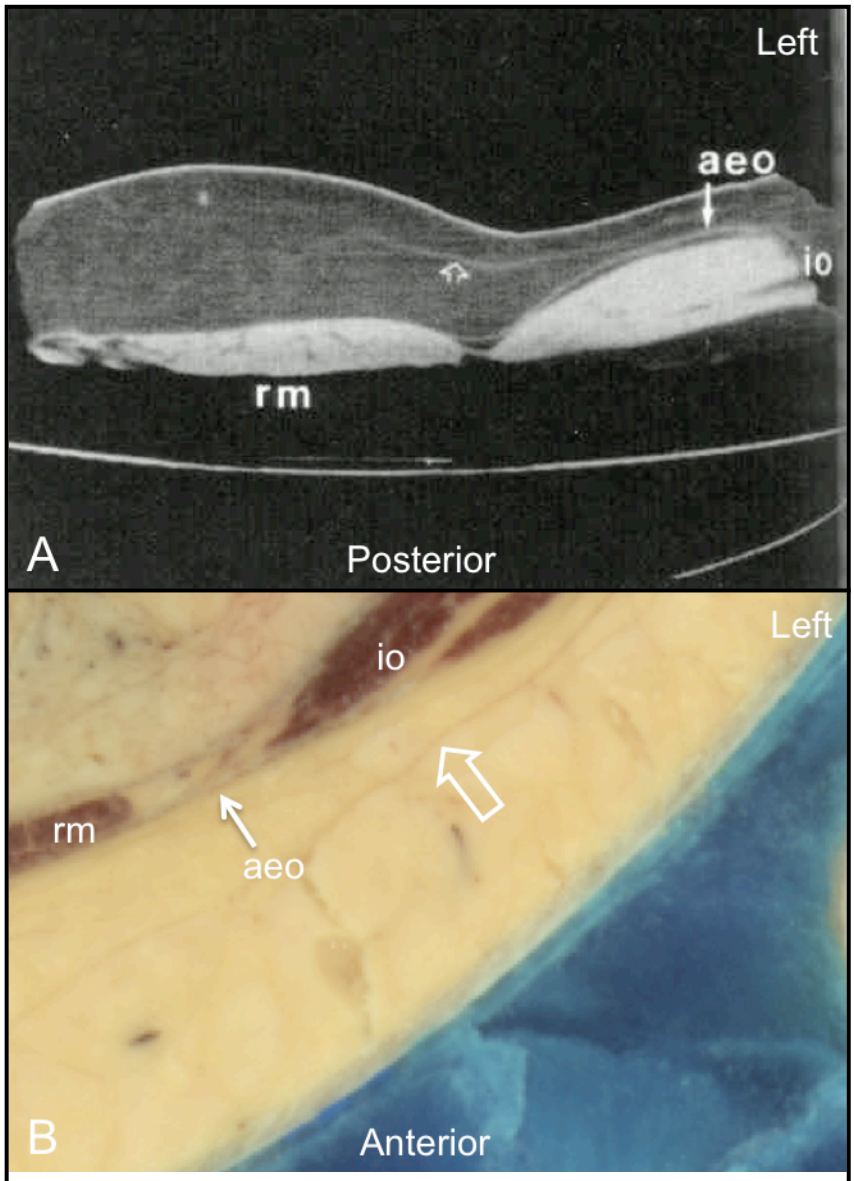

Figure 2-5. Identifying Scarpa's fascia in the Visible Human Project by comparing to a computed tomography image of the anterior abdominal wall. (A) Computed tomography of the anterior abdominal wall. (B) Visible Human Project cryosection of the anterior abdominal wall. *(Hollow Arrow) Scarpa's fascia, (rm) Rectus abdominus, (io) Internal oblique, (aeo) External oblique aponeurosis. Image Source: (A) Worseg et al., (B) Visible Human Project*

between a male and a female.

The cryosection data set were cross section images, cut in 0.33 mm intervals for the female and 1 mm intervals for the male[42]. Therefore to examine the membranous layer with respect to a particular sign, the cryosections corresponding to that level were examined. With respect to Cullen's sign, cryosection images covering the span of the umbilicus were examined. In examining Turner's sign, cryosection images covering the flanks were examined. Finally for icterus marginatus, cryosection images covering the thoracic region were analyzed. Worseg et al identified the membranous layer of superficial fascia (Scarpa's fascia) as a dense white line surrounded by a darker region (Camper's fascia) in a computed tomography (CT) of the anterior abdominal wall[27]. Using this CT image, Scarpa's fascia was identified in the Visible Human Project data sets. In the Visible Human Project, the cryosections are photographed images of the actual specimen. Therefore, in contrast to the computed tomography image, Camper's fascia appeared as a yellow-white region and Scarpa's fascia appeared as a dense dark line within this region (figure 2-5). Furthermore, the identification of Scarpa's fascia was verified by identifying the different layers of the anterior abdominal wall from superficial to deep; Skin, Camper's fascia, Scarpa's fascia, external oblique aponeurosis, anterior abdominal muscles and peritoneal cavity[41] (figure 2-6).

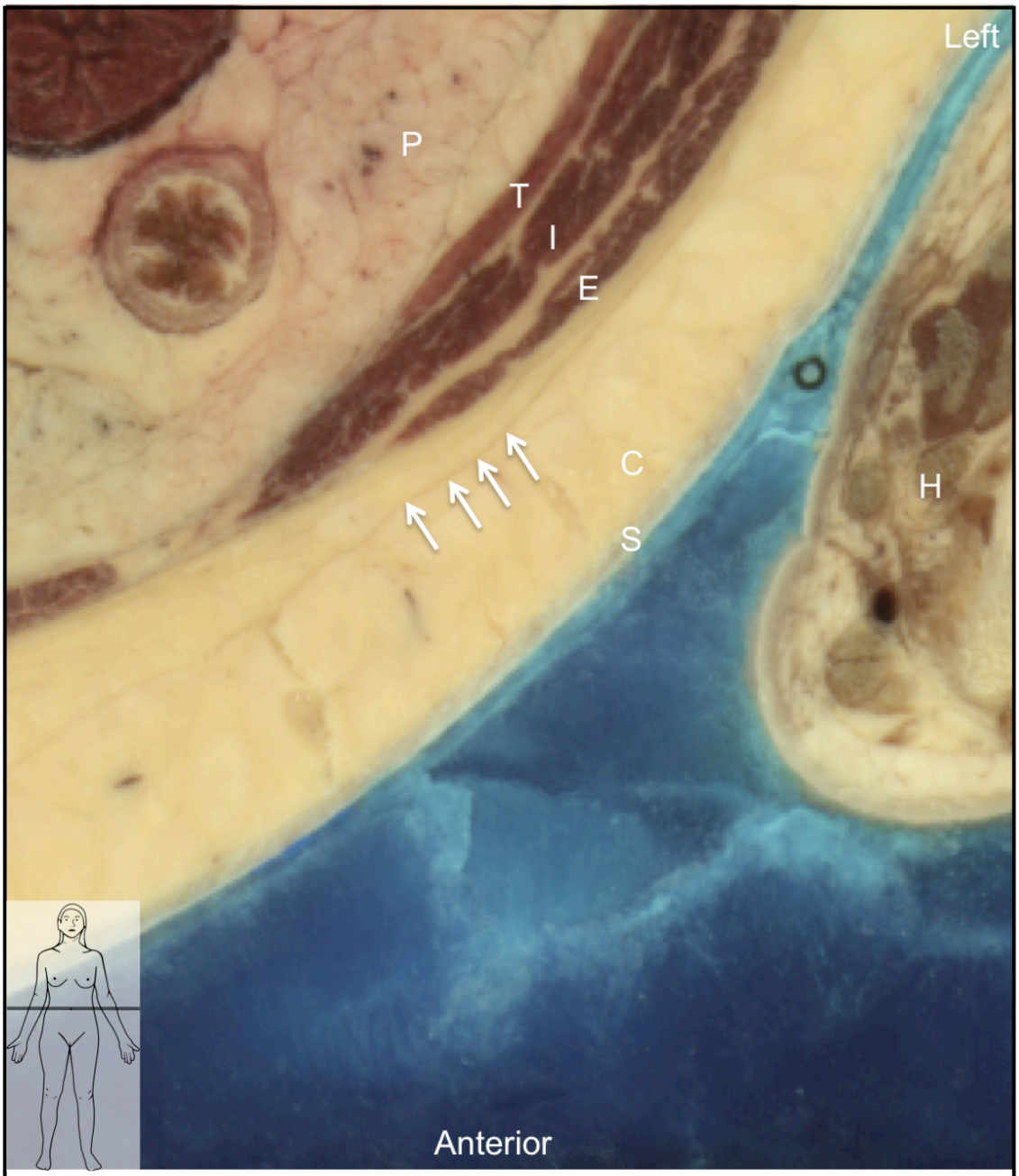

Figure 2-6. Identifying Scarpa's fascia by the layers of the anterior abdominal wall. *(S) Skin, (C) Camper's fascia, (White arrows) Scarpa's fascia, (E) External oblique, (I) Internal Oblique, (T) Transversus abdominus, (P) Peritoneal cavity, (H) Left arm. Image Source: Visible Human Project*

3.1 The Demonstration of a Continuous Membranous Layer

The deep membranous layer of superficial fascia, which is otherwise known as Scarpa's fascia in the abdomen, was found to exist in the abdomen and the chest. The membranous layer was followed laterally until it reached the edges of the upper and lower back (figure 3-1). The membranous layer remained loosely attached in the abdomen, the flanks and the axilla (discussed below).

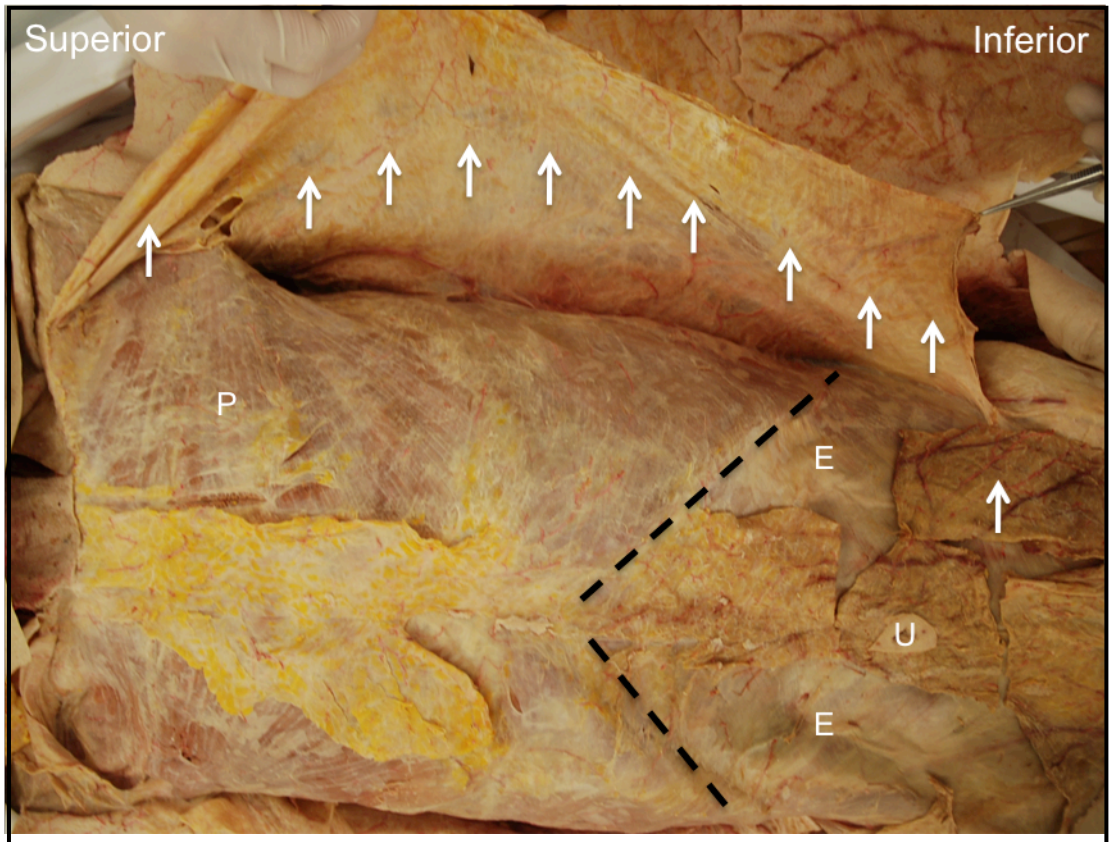

Figure 3-1. Demonstration of the continuous membranous layer. *(White arrow) The deep membranous layer of superficial fascia. (E) External oblique aponeurosis, the layer deep to Scarpa's fascia in the abdomen. (U) Umbilicus. (P) Pectoralis major, (Dashed lines) Costal Margin.*

3.2 Cullen's Sign

Dissections

Scarpa's fascia appeared as two distinct pockets that did not communicate in three of the subjects (figure 3-2). However in one of the subjects it appeared that there was a direct connection between both sides of the abdomen (figure 3-3).

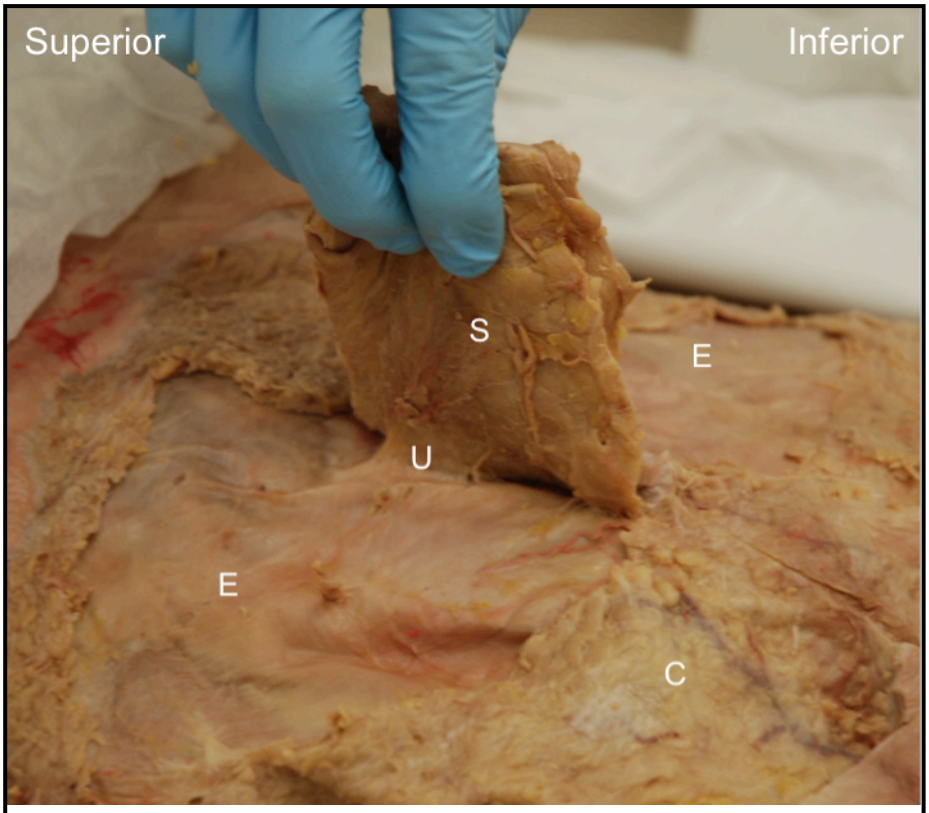

Figure 3-2. Example of a subject where the two Scarpa's fascia pockets do not communicate. In these cases, Scarpa's fascia adheres to the midline of the abdomen. *(U) Umbilicus, (S) Scarpa's fascia, (E) External oblique aponeurosis, (C) Camper's fascia*

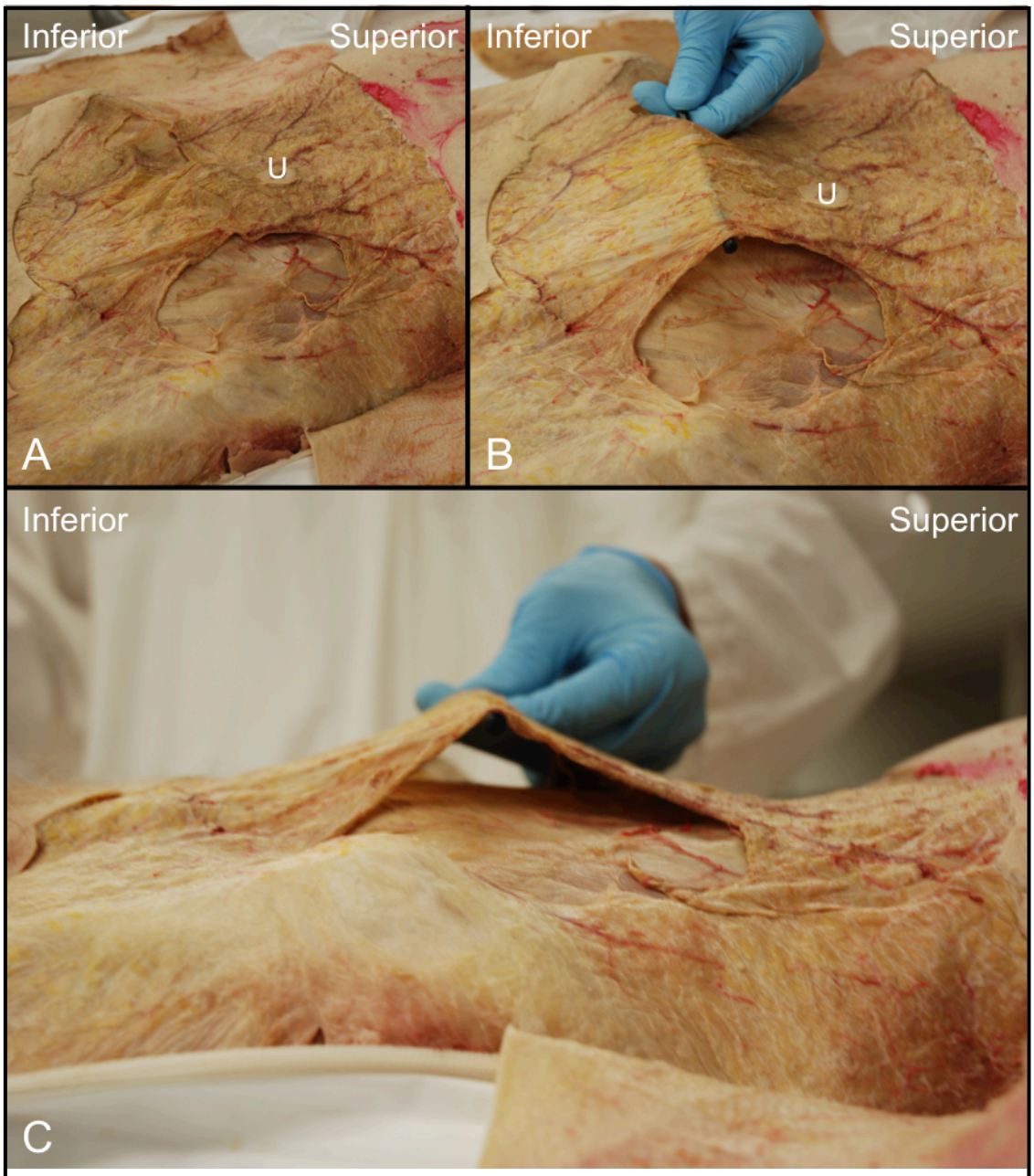

Figure 3-3. Direct communication of Scarpa's fascia between both sides of the abdomen. (A) Scarpa's fascia, incised on both sides. (B) Demonstration of the communication between both sides of the abdomen. (C) Different angle showing the continuation of the pocket created by Scarpa's fascia on both sides of the abdomen. *(U) Umbilicus*

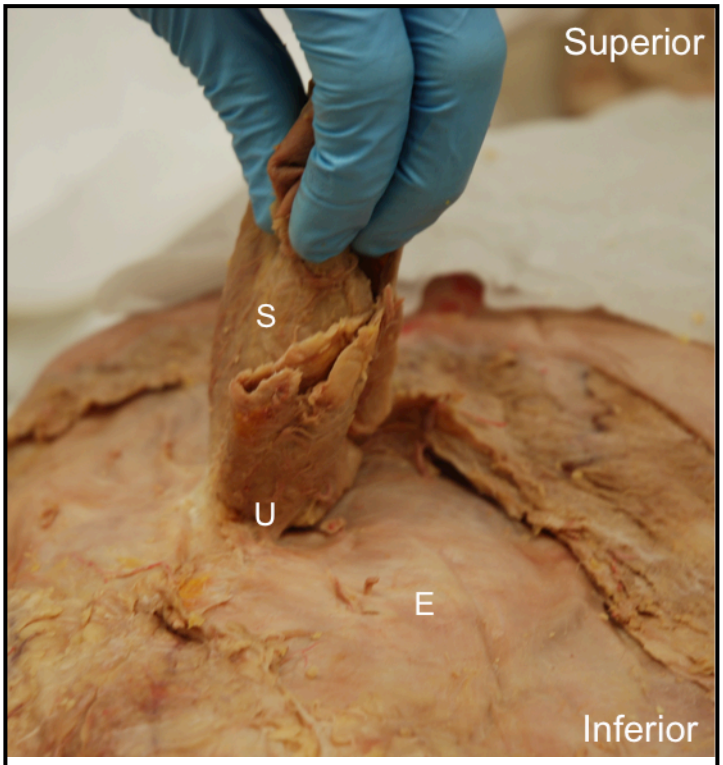

Figure 3-4. Demonstration of Scarpa's fascia's attachment to the umbilicus. *(U) Umbilicus, (S) Scarpa's fascia, (E) External oblique aponeurosis*

Upon elevating Scarpa's fascia it appeared secured to the abdomen around the periumbilical region, while remaining relatively loose elsewhere (figure 3-4).

Scarpa's fascia was released laterally so that it was only attached to the umbilicus. It was clear that Scarpa's fascia was firmly attached to the umbilicus along the entire perimeter (figure 3-5). The umbilicus was then removed from the abdomen. Upon examination, the underlying external oblique aponeurosis was absent in this region and the remnants of the round ligament was present (figure 3-6).

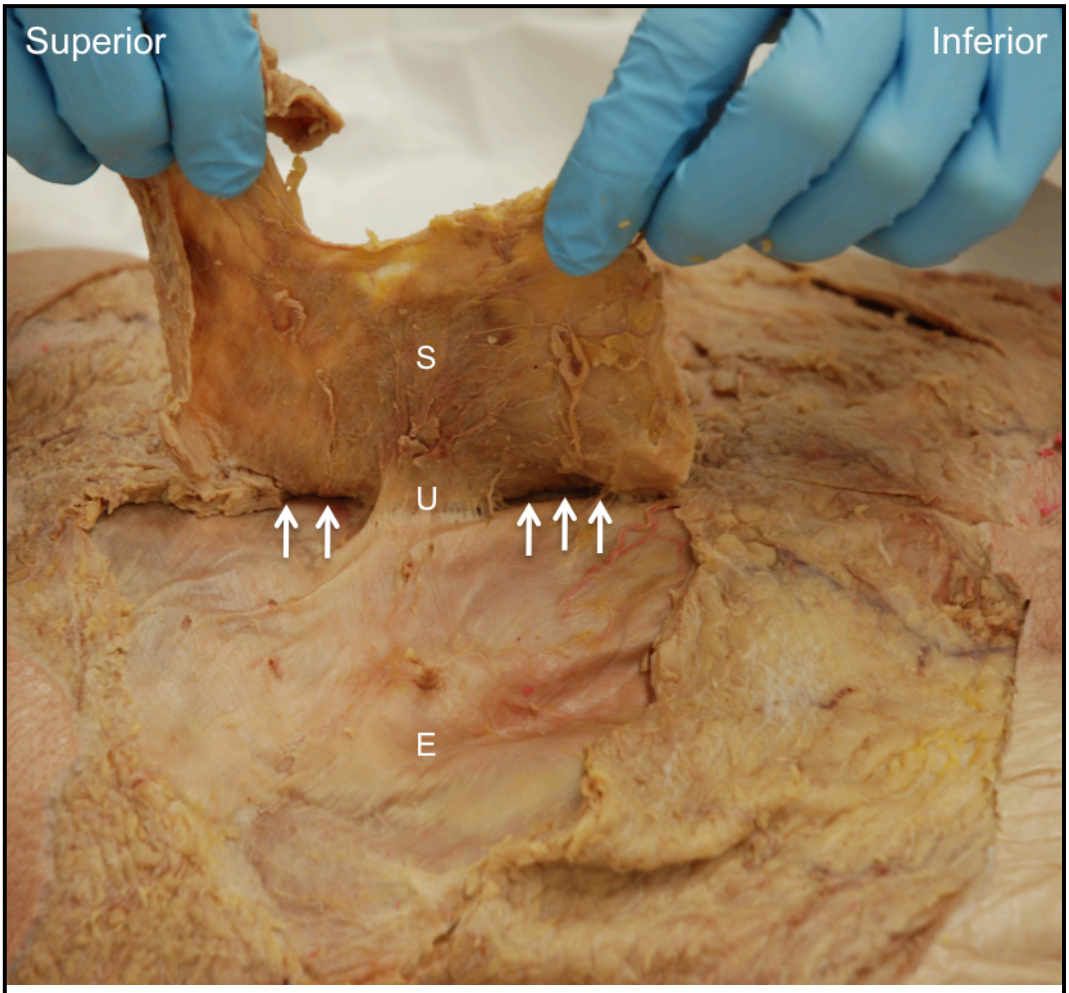

Figure 3-5. Demonstration of Scarpa's fascia attached to the umbilicus but remaining relatively loose elsewhere (White arrow). *(U) Umbilicus, (S) Scarpa's fascia, (E) External oblique aponeurosis*

Staining (Post 24 hours)

Sudan black mineral oil remained in left pocket. Solution did not reach the area around the umbilicus. The periumbilical region remained free from solution (figure 3-7).

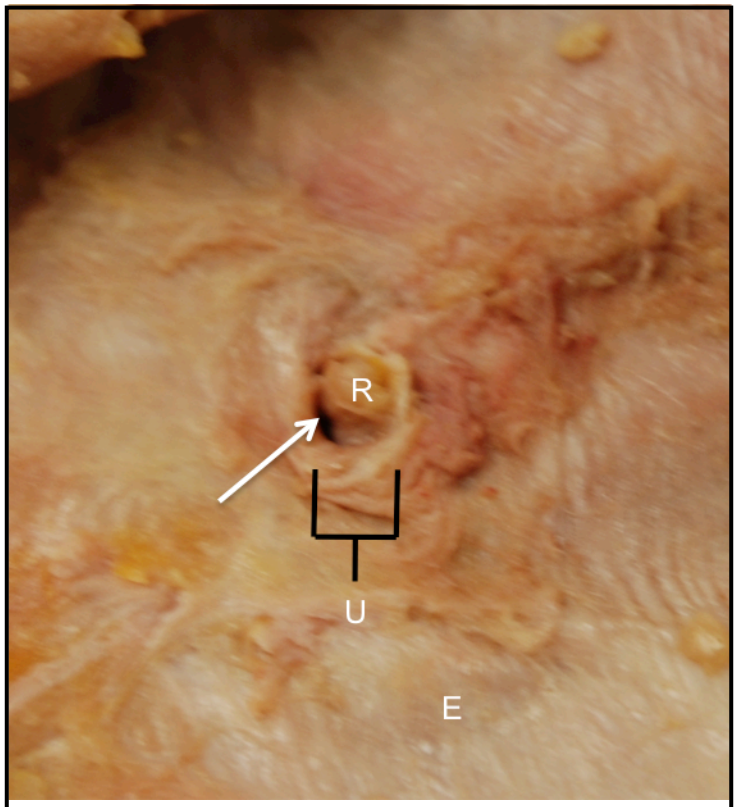

Figure 3-6. Demonstration of the umbilicus detached from the abdominal wall. *(White arrow) Deficiency of external oblique aponeurosis. (R) Round ligament of the liver. (E) External oblique aponeurosis. (U) Umbilicus*

Visible Human Project

As stated, the female cryosections were used due to the superior image quality of this data set. Upon examination of the umbilicus, it was noted that the membranous layer followed into the umbilicus where it attached. This created an area in the midline where the umbilicus emerged that was devoid of Scarpa's fascia (figure 3-8).

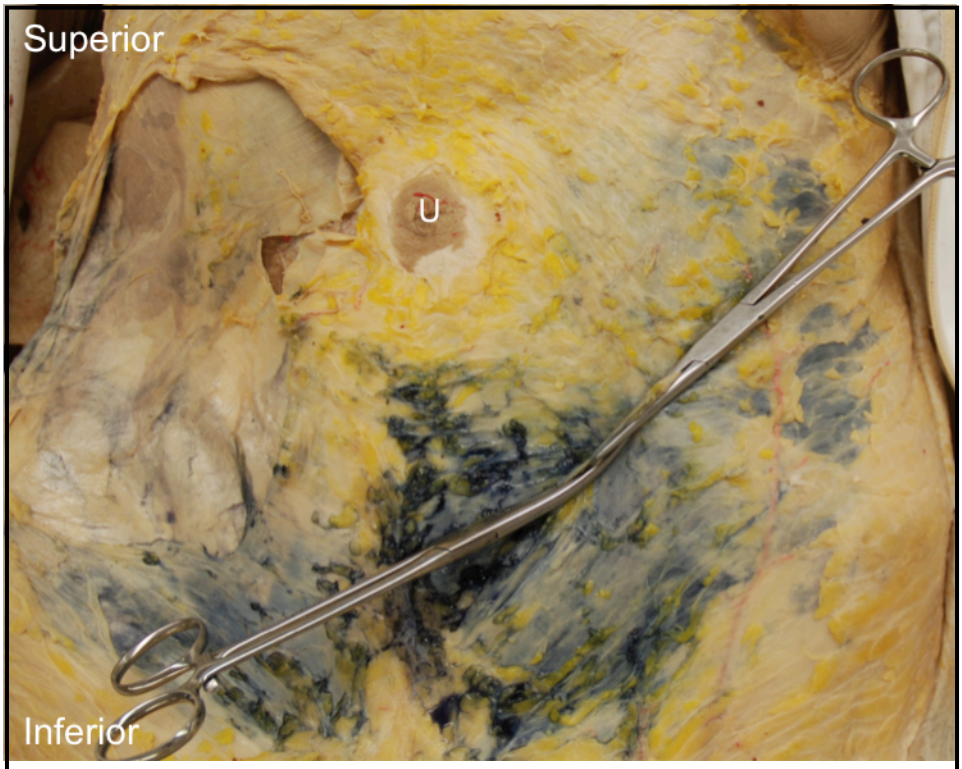

Figure 3-7. Sudan black mineral oil solution in the left pocket created by Scarpa's fascia post 24 hours. Right pocket, Scarpa's fascia has been removed, revealing the underlying external oblique aponeurosis. *(U) Umbilicus*.

3.3 Turner's Sign

Dissections

As the membranous layer of superficial fascia (Scarpa's fascia) continued laterally, it was found to attach to the lateral edges of the abdomen (figure 3-9). As the membranous layer continued laterally to the flank it revealed an area where it was found to loosely attached to the underlying connective tissue.

This loose region was incised and then explored. This loosely attached area

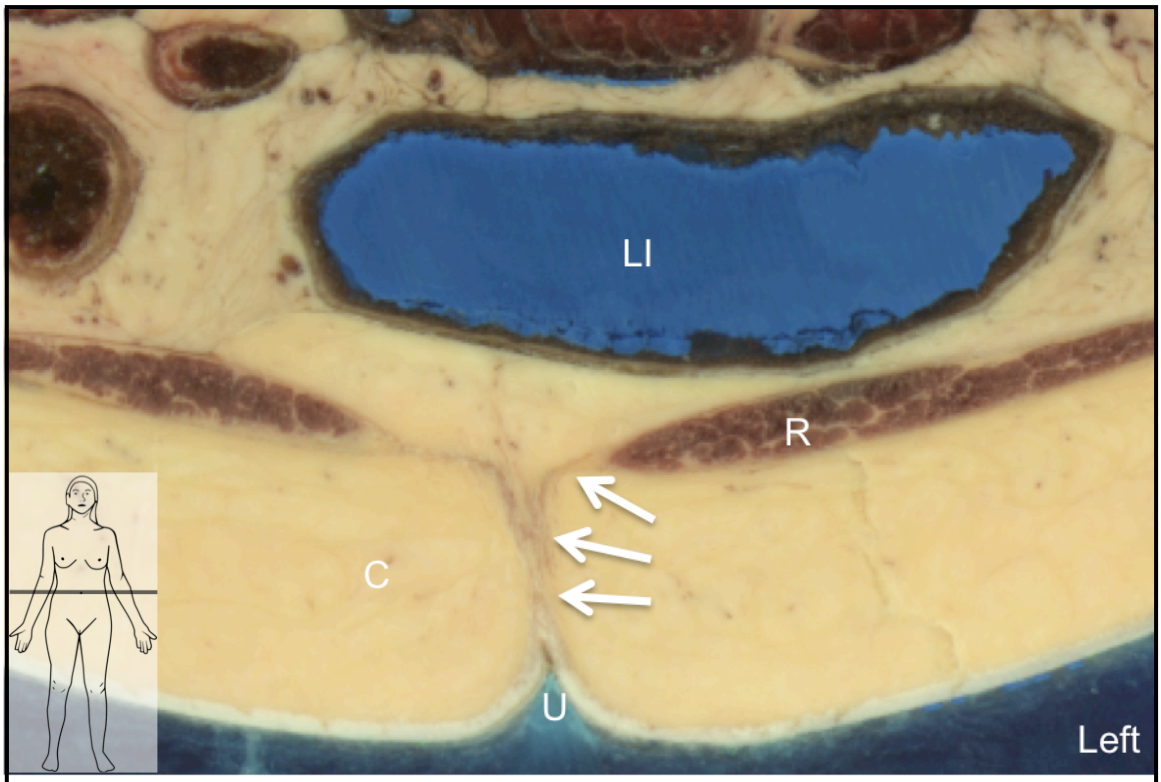

Figure 3-8. The attachment of Scarpa's fascia to the umbilicus. Due to the nature of Scarpa's fascia's attachment to the umbilicus, retroperitoneal fluid upon entering the umbilicus via the falciform ligament is constrained around the umbilicus. *(R) Rectus abdominus. (LI) Large intestine. (C) Camper's fascia. (U) Umbilicus. (White arrows) Scarpa's fascia. Image Source: Visible Human Project*

extended superiorly to just below the costal margin, inferiorly to just above the pelvic crest, anteriorly it attached before reaching the abdomen and posteriorly it attached before reaching the lower back (figure 3-10). This loose region was composed of the membranous layer of superficial fascia. The floor appeared to be continuous with the connective tissue found underneath Scarpa's fascia in the abdomen (figure 3-11).

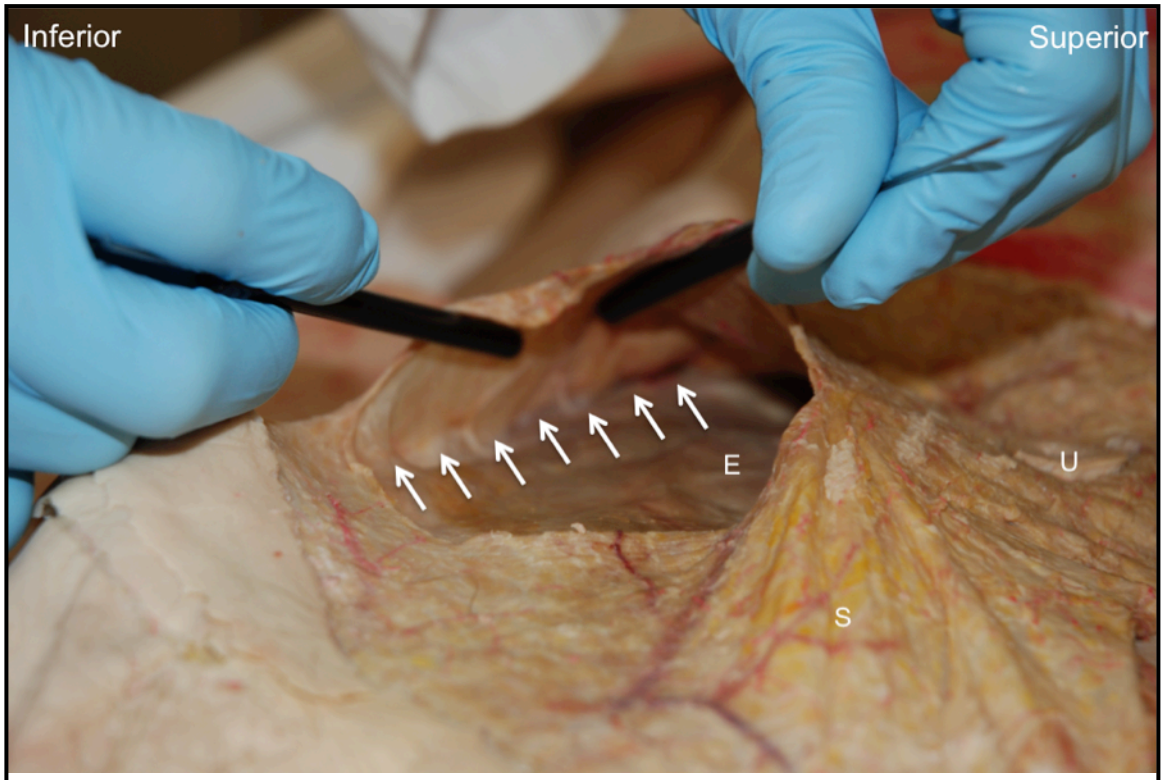

Figure 3-9. Demonstration of Scarpa's fascia attaching to the lateral edge of the abdomen. In this figure, the right pocket is demonstrated. *(White arrows) Lateral border of the pocket created by Scarpa's fascia, (U) Umbilicus, (E) External oblique aponeurosis, (S) Scarpa's fascia*

Staining (Post 24 hours)

Sudan black mineral oil remained in the loosely attached region of the membranous layer. The solution did not extend beyond the region's limits (figure 3-12).

Visible Human Project

The female cryosection data set was also used for this sign. The lateral flanks of the cryosections were analyzed at the level of the left kidney hilum. Investigation revealed the membranous layer in the lateral flank. Furthermore, the membranous layer appeared loosely attached in close relationship to the superior

triangle of Grynfelt-Lesshaft (figure 3-13).

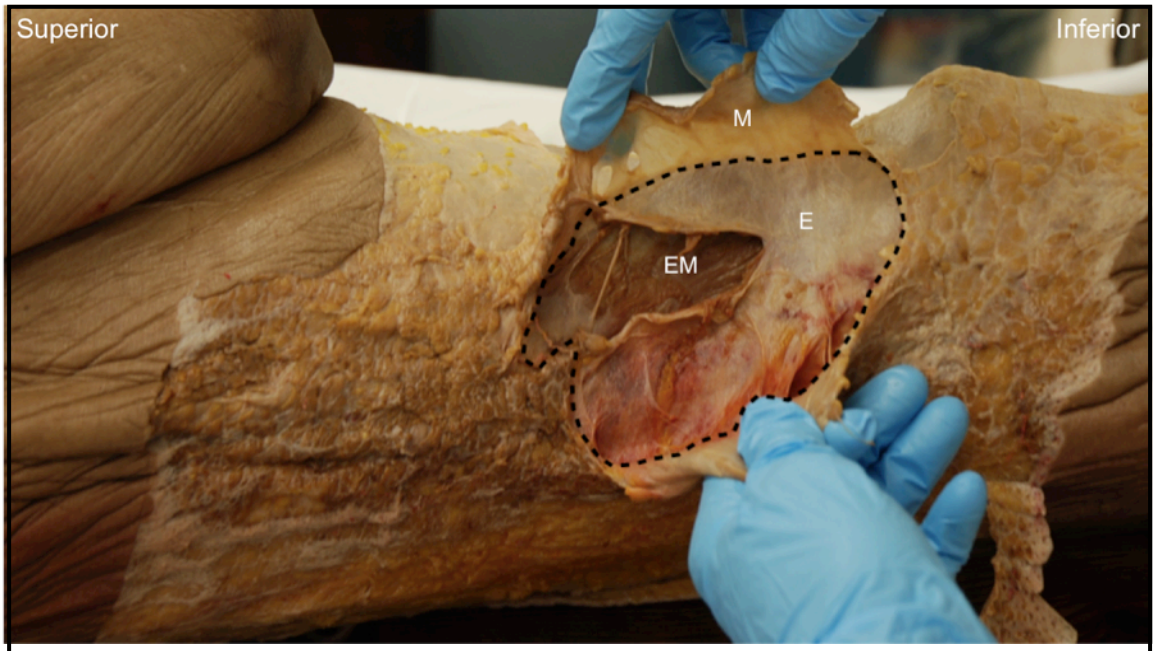

Figure 3-10. Demonstration of the membranous layer loosely attached in the flank. *(Dashed line) Region where the membranous layer is loosely attached in the flank, (M) Membranous layer, (E) External oblique aponeurosis, (EM) External oblique muscle*

3.4 Icterus Marginatus

Dissections

As the membranous layer of superficial fascia (Scarpa's fascia) continued superiorly, it attached to the underlying connective tissue just inferior to the costal margin (figure 3-14). As the membranous layer continued into the chest and axilla, a loosely attached region was found.

This loose region was incised and then explored. Superiorly, the loosely attached area extended to just below the superior limits of the axilla. Inferiorly the loosely attached region attached to the thoracic cage anywhere from the rib 6 to rib 9

level. Laterally, the loosely attached region gradually attached to the anterior chest wall (figure 3-15). The region was firmly attached to the nipple, while areas around the nipple remained loose.

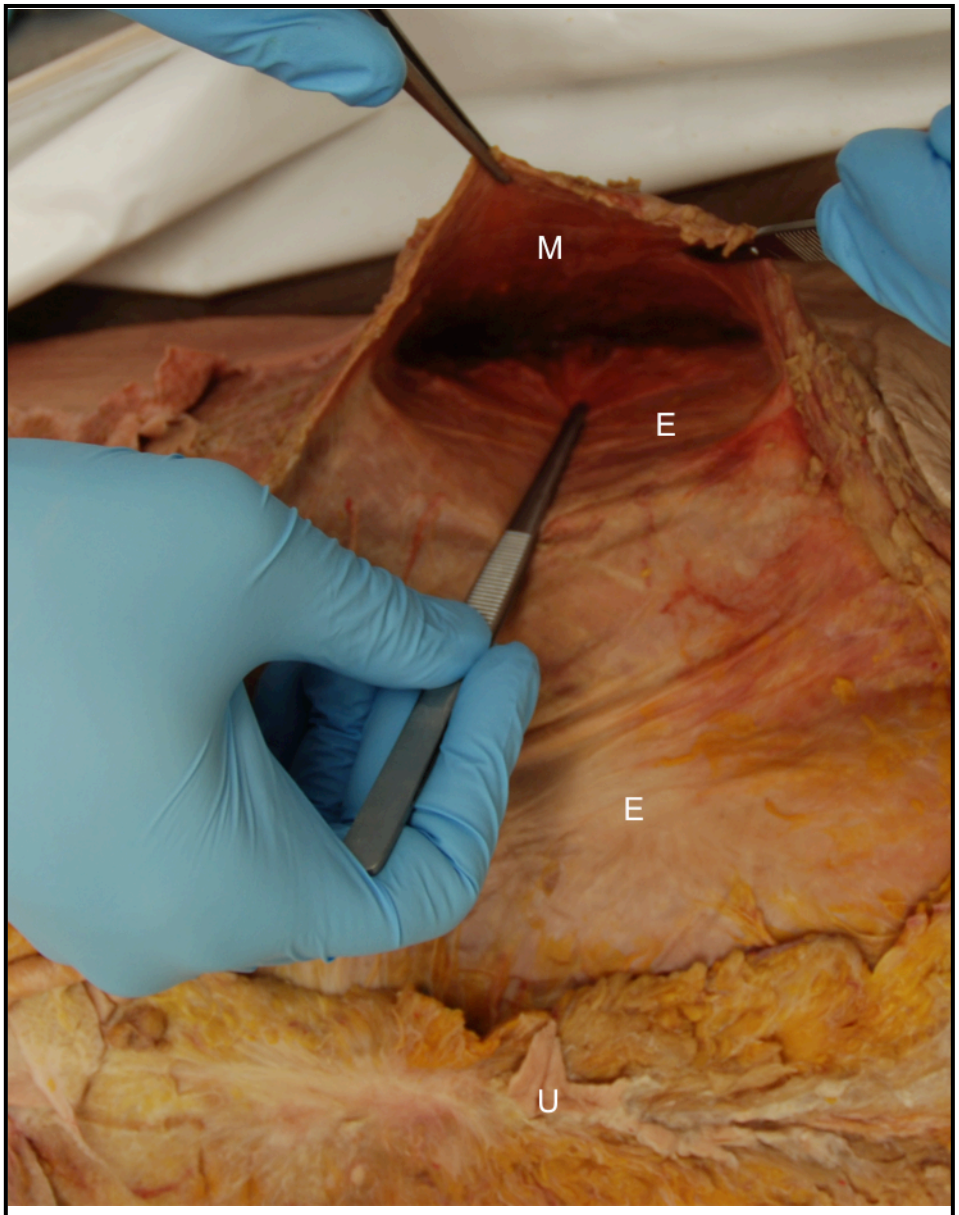

Figure 3-11. Demonstration of the continuation of the connective tissue underlying Scarpa's fascia in the abdomen into the lateral flank. *(M) Membranous layer, (E) External oblique aponeurosis, (U) Umbilicus.*

Staining (Post 24 hours)

Sudan black mineral oil remained in the loosely attached region. The solution did not extend beyond the region's limits. The solution spread around the nipple, but did not reach the nipple itself (figure 3-16).

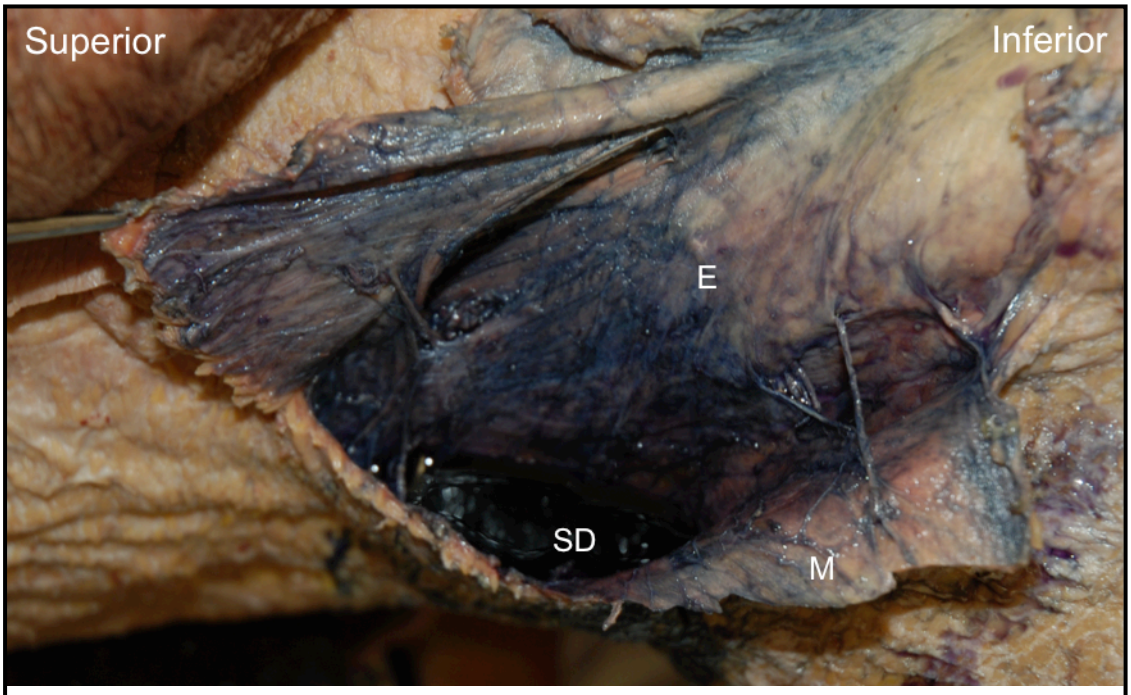

Figure 3-12. Demonstration of Sudan black mineral oil solution remaining in the loosely attached region of the membranous layer in the lateral flank. *(E) External oblique aponeurosis, (M) Membranous layer, (SD) Sudan black mineral oil solution*

Visible Human Project

As stated previously, the male cryosection data set was used for this investigation. While the membranous layer was noted in the sections, there was no indication of a loosely attached region in the chest and axilla (figure 3-17).

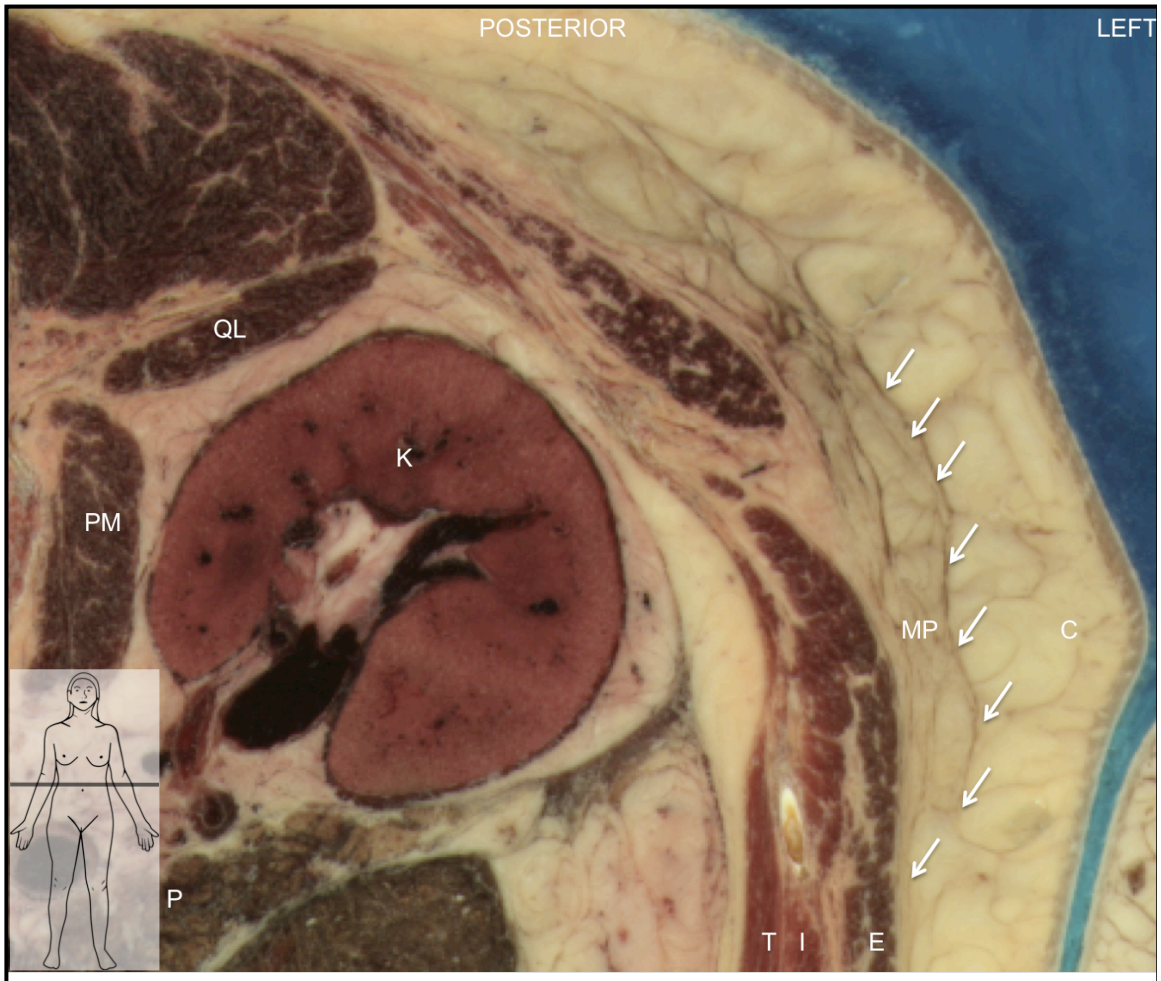

Figure 3-13. Loosely attached region of the membranous layer in the left flank. *(PM) Psoas major. (QL) Quadratus lamborum. (K) Left kidney. (P) Pancreas. (T) Transversus abdominus. (I) Internal oblique. (E) External oblique. (MP) Loosely attached region of membranous layer. (C) Camper's fascia. (White arrows) Membranous layer. Image Source: Visible Human Project.*

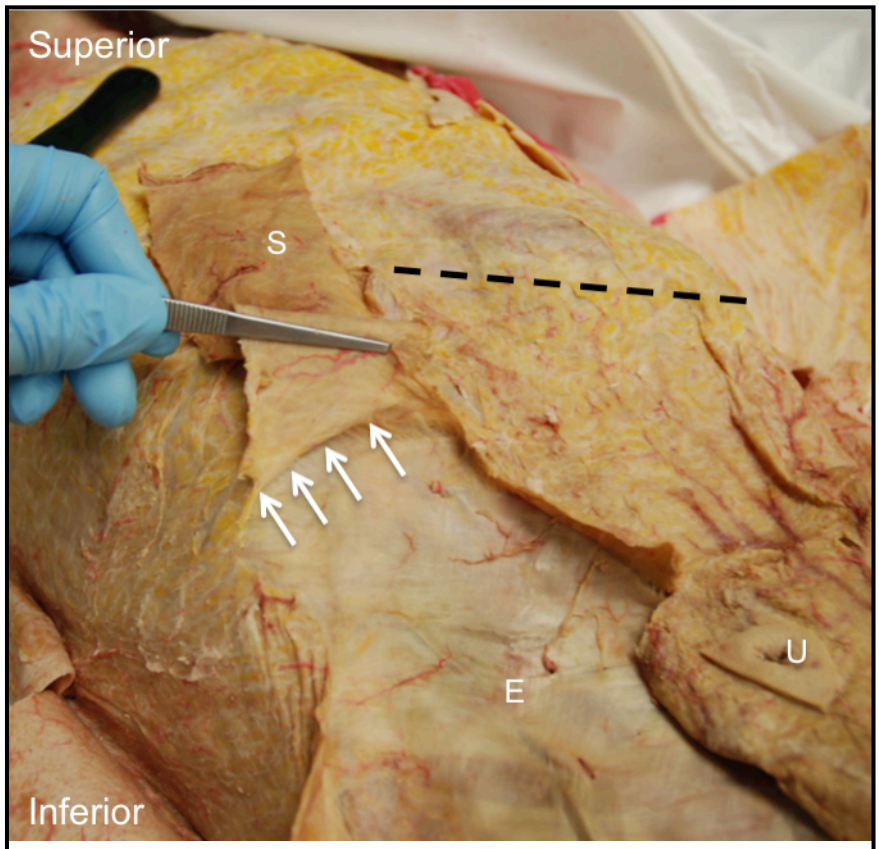

Figure 3-14. Demonstration of Scarpa's fascia's superior attachment (White arrow) just below the costal margin. *(Dashed lines) Costal margin, (S) Scarpa's fascia, (E) External oblique aponeurosis, (U) Umbilicus*

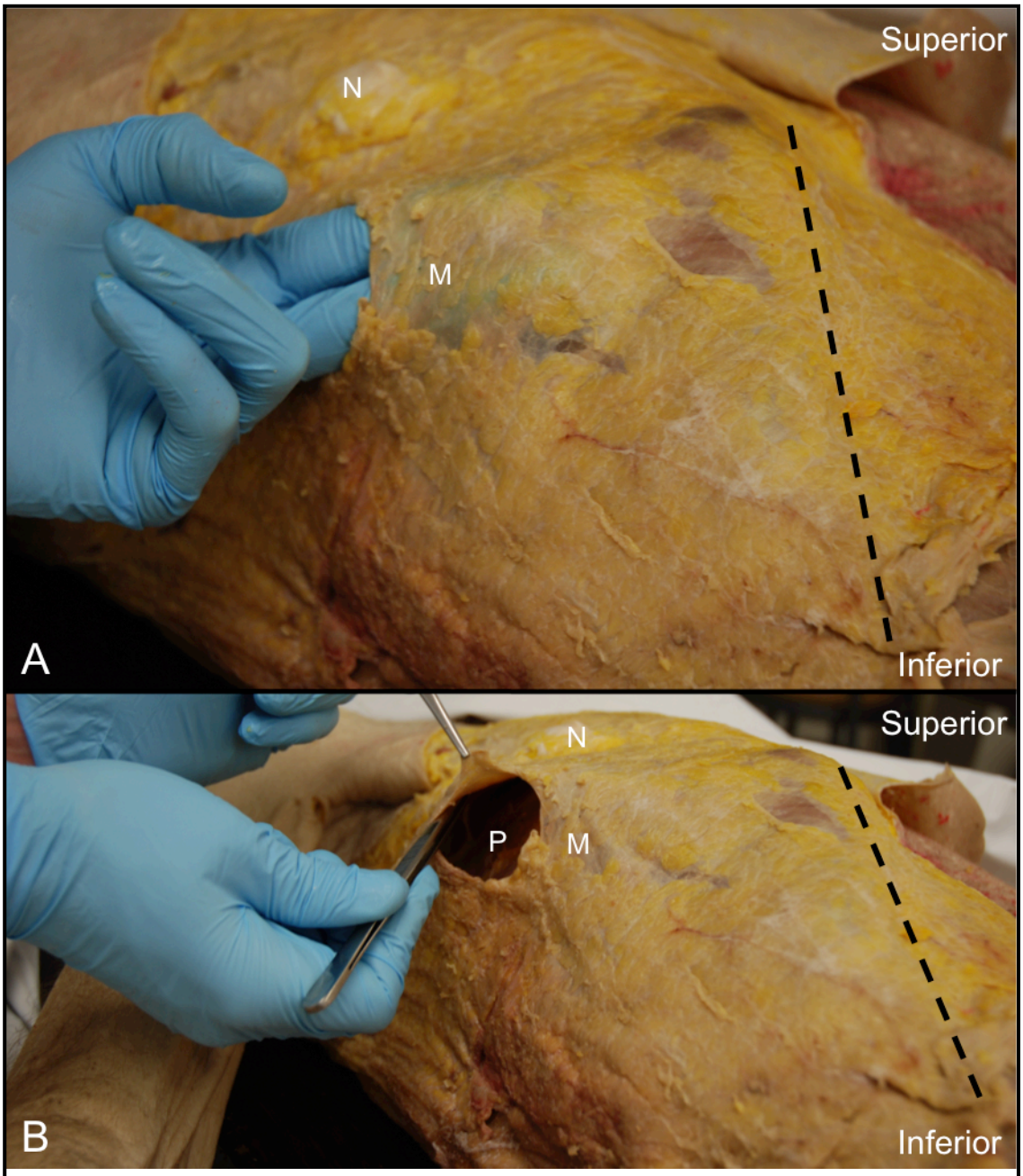

Figure 3-15. Demonstration of the membranous layer loosely attached at the axilla. (A) Demonstrates the membranous layer's attachment along the costal surface. (B) Demonstrates the extent of the membranous layer's loose attachments at the axilla. *(Dashed lines) Costal margin, (N) Nipple, (M) Membranous layer, (P) Pectoralis major*

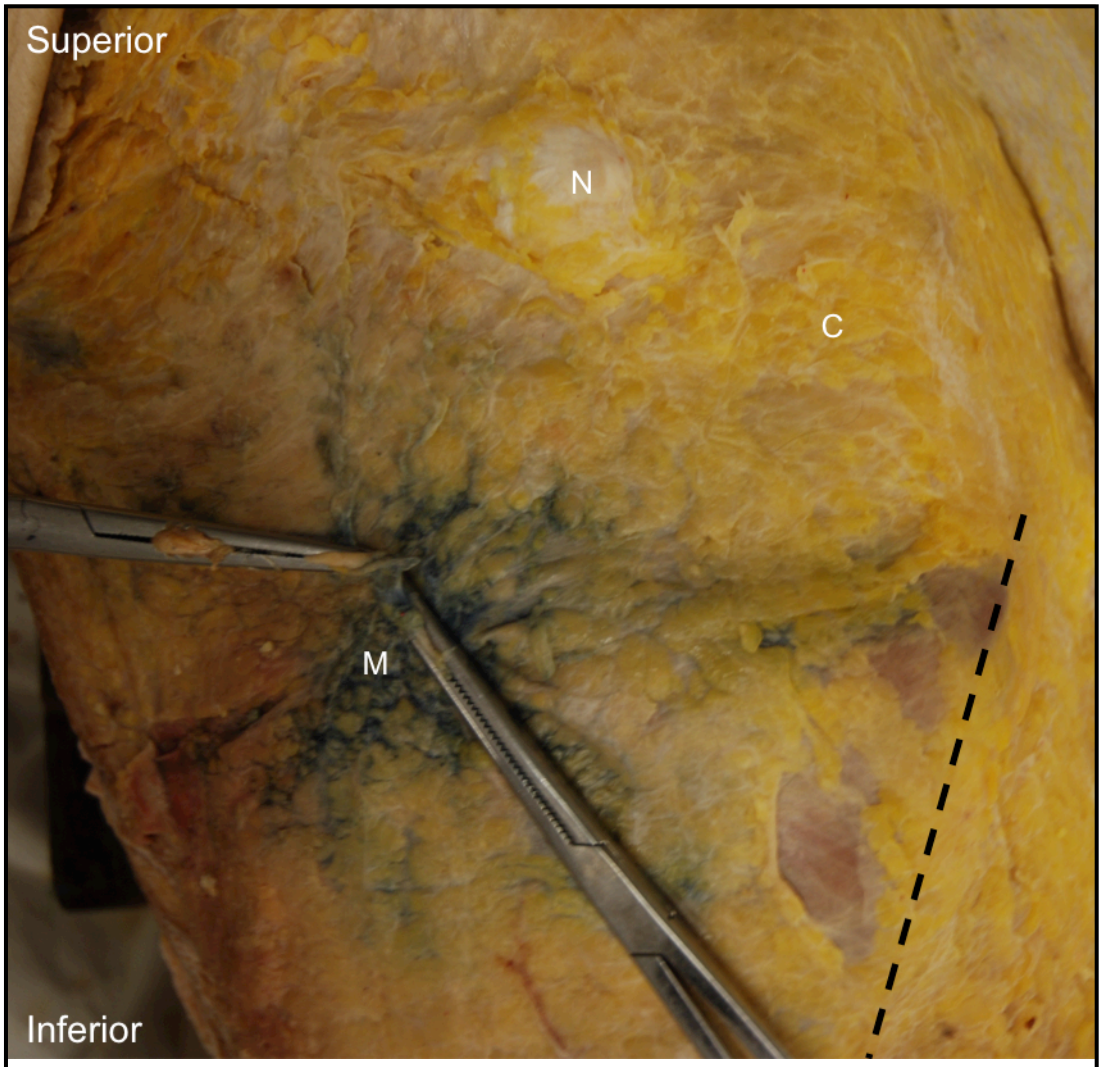

Figure 3-16. Demonstration of Sudan black mineral oil solution contained in the loosely attached region of the membranous layer in the axilla. Solution did not reach the nipple. Post 24 hours*. (Dashed lines) Costal margin, (M) Membranous layer, covering sudan black mineral solution, (N) Nipple, (C) Camper's fascia*

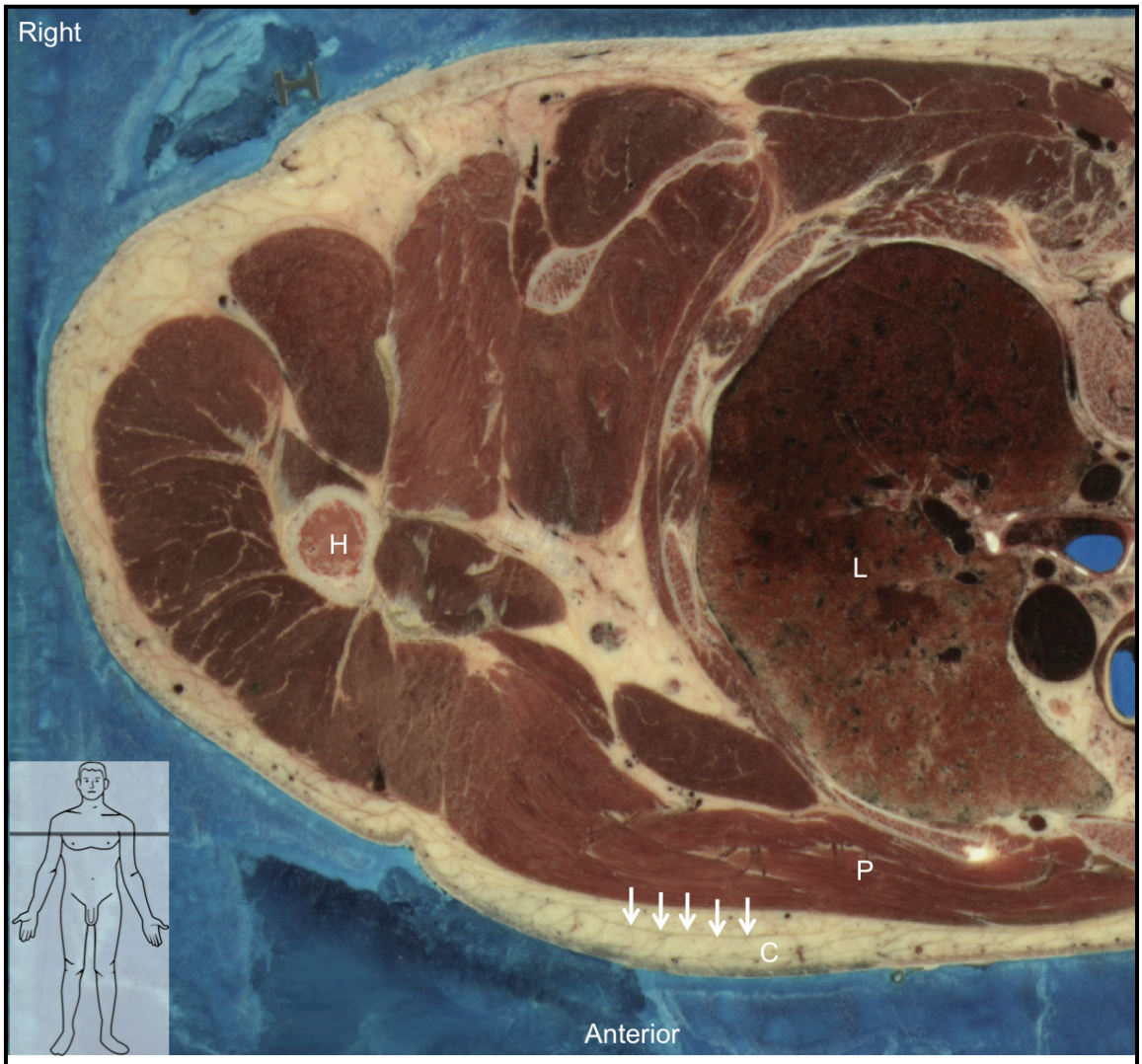

Figure 3-17. Male cryosection image showcasing the membranous layer (White arrows). *(C) Camper's fascia. (P) Pectoralis muscles. (H) Shaft of the humerus. (L) Right lung. Image Source: Visible Human Project*

- Discussion -

4.1 General

Evidence for a continuous membranous layer was initially presented by Abu-Hijleh et al, who analyzed the thickness of the membranous layer of superficial fascia from various areas of the body. Traditionally, the membranous layer, otherwise known as Scarpa's fascia, is referred to as a thickening of Camper's fascia in the abdomen[40]. Here Scarpa's fascia forms two oval pockets that continues inferiorly to become Colle's fascia[4]. Yet with the demonstration of a continuous membranous layer, the possibility exists that the pockets that Scarpa's fascia forms in the abdomen can also exist in different areas of the body. The dissections demonstrated this continuous membranous layer by following Scarpa's fascia superiorly to the clavicle and laterally to the borders of the upper and lower back. Subsequently, the dissections were able to demonstrate loosely attached regions of the membranous layer in the flanks and the axilla. These areas provide potential capsules for retroperitoneal fluid to accumulate in and present subcutaneously.

As a result, this study has demonstrated potential areas within the membranous layer of superficial fascia for which the clinical signs Cullen's, Turner's and icterus marginatus can manifest. The attachment of Scarpa's fascia into the umbilicus circumferentially explains why the bruising is limited to the peri-umbilical region. Conversely, the finding of the loosely attached region of the membranous layer in the flank help explains why retroperitoneal fluid only remains in the flank and

does not travel inferiorly due to gravity. Finally, the finding of the loosely attached region of the membranous layer in the axilla help explains the bile staining on the lateral chest walls seen in icterus marginatus. The findings in this project are consistent with the findings of Abu-Hijleh et al who have described that the membranous layer of superficial fascia is continuous throughout the body. In addition, the results in this study align with work done by Meyers et al who tracked the flow of retroperitoneal fluid in Turner's and Cullen's signs[35]. The location of the pocket in the flank and Scarpa's fascia's attachment to the umbilicus related closely to the proposed pathways established for Turner's sign and Cullen's sign respectively.

In addition to the cadaveric dissections, transverse cryosections from the Visible Human Project were analyzed. Close investigation of the female cryosections revealed findings consistent with the dissections performed in this study for Cullen's sign and Turner's sign. The female cryosections demonstrated the attachment of Scarpa's fascia into the umbilicus, thereby creating a capsule for retroperitoneal fluids to accumulate around the umbilicus. Furthermore, investigation of the lateral flanks in the cryosections revealed a loosening of the membranous layer in close proximity to the dissections for Turner's sign. Investigation of the axilla and chest revealed the presence of a membranous layer, however it did not show a similar arrangement to that seen in Turner's sign to suggest loose attachments. There are several possibilities for this. During the dissections there was more adipose tissue in the flanks than there was in the

chest. Similarly in the cryosections, the thickness of Camper's fascia was greater in the flanks than in the axilla and chest. As a result, it made it difficult to discern the membranous layer and its possible arrangements. Furthermore, all axilla and chest dissections were performed on a male cadaver. The reason behind this was two-fold. First, the case of icterus marginatus occurred in a male patient. Second, in females the fascia system differs in the chest due to the mammary glands[40,42]. Therefore, the axilla and chest dissections were focused on male cadavers because of the relevance to the case. That being said, this may explain why a similar arrangement of the membranous layer was not found on the female cryosections. As for the male cryosections, the layer of Camper's fascia was thinner in the chest than it was in the flanks. This made it difficult to observe the arrangement of the membranous layer in the axilla and the chest.

The likelihood that signs such as Turner's sign and icterus marginatus are indeed due to fluid accumulation in closed subcutaneous pockets is convincing. If one looks at a clinical presentation of Turner's sign, it is noted that the bruising appears ovoid. One would expect a diffused appearance due to gravity, however this is not noted. It appears as if the fluid is suspended in an enclosed cavity. Similarly for icterus marginatus, biliary staining was bi-lateral and absent around the area of the nipple. One would expect the bile to diffuse across the chest instead of being sharply delineated on each side, yet this is precisely what happens in icterus marginatus. It is these clinical presentations that support the case for potential pockets to exist in the body besides the abdomen.

4.2 Understanding the Pathway

The trend for Cullen's and Turner's has long been that whatever the cause, the origin of fluid is almost always retroperitoneal[9,18]. This is likely the case for icterus marginatus as well.

An important consideration is how to make the connection between the origin of the fluid, how it gets into the retroperitoneum and finally how it manifests in subcutaneous tissue. To understand the potential pathways of these signs, an understanding of the retroperitoneum is required.

General

The retroperitoneum is a fat filled compartment that houses various organs. It is bordered anteriorly by the parietal peritoneum and posteriorly by transversalis fascia. Superiorly the retroperitoneum extends to the diaphraghm and inferiorly it reaches the pelvic cavity.

The organs in the retroperitoneum include the adrenal glands, kidneys, ureters, gonads, aorta, inferior vena cava, pancreas, the 2nd and 3rd parts of the duodenum, ascending and descending colon, bladder, prostate, seminal vesicles and the uterus.[29,30].

Compartments

The retroperitoneum is divided into three compartments with respect to the kidney; the anterior pararenal space, the perirenal space and the posterior pararenal space (figure 4-1).

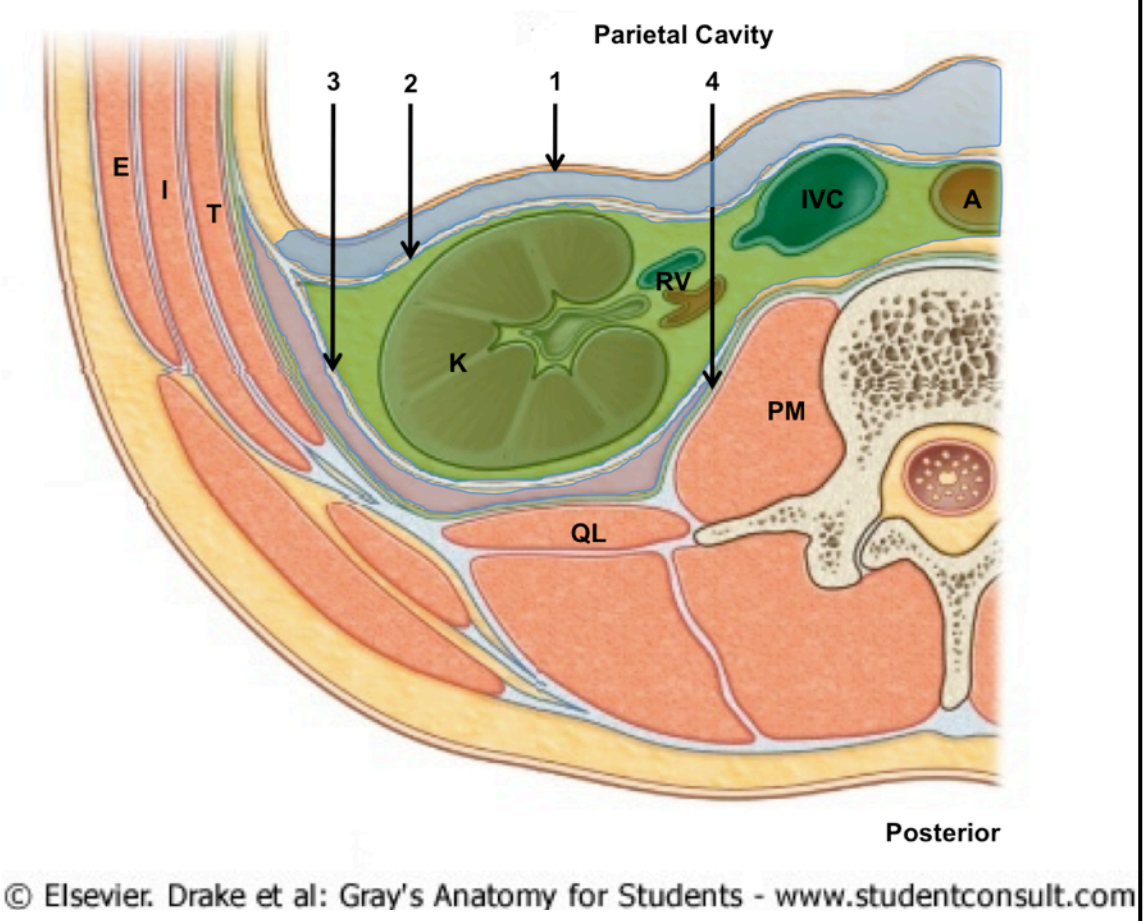

Figure 4-1. The compartments of the retroperitoneum. *(Blue) Anterior pararenal space, (Green) Perirenal space, (Purple) Posterior pararenal space (1) Posterior parietal peritoneum, (2) Anterior renal fascia, (3) Posterior renal fascia, (4) Transversalis fascia, (E) External oblique, (I) Internal oblique, (T) Transversus abdominus, (K) Kidney, (RV) Renal vessels, (IVC) Inferior vena cava, (A) Aorta, (QL) Quadratus lumborum, (PM) Psoas major. Image Source: Drake et al.*

Anterior Pararenal Space

This space is located between the posterior parietal peritoneum and the anterior renal fascia. It contains a large amount of adipose as well as the 2nd and 3rd parts of the duodenum, ascending and descending colons and the pancreas[29].

The anterior pararenal space has direct connections with the peritoneal cavity via the following relationships; 1) reflection of the coronary ligament to the bare area of the liver, 2) hepatoduodenal ligament and 3) gastrohepatic ligament which is continuous with the falciform ligament[31]. These connections allow a pathway for the transfer of fluid between the retroperitoneum and the peritoneal cavity.

Perirenal Space

This space is located between the anterior renal fascia and the posterior renal fascia. The perirenal space is conceptualized as a cone (with the tip of the cone pointed inferiorly). As such, when moving inferiorly from the kidneys, the perirenal space narrows. The renal fascia combine superiorly to form the suspensory ligament which attaches to the diaphragm. The perirenal space consists of the kidneys, adrenal glands and associated renal vessels. The area also contains large amounts of adipose tissue.

It is postulated that since the perirenal space tapers inferiorly, it is a potential pathway for the anterior pararenal space to communicate with the posterior pararenal space[29].

Renal Fascia

From anterior to posterior, one will encounter the anterior pararenal space, anterior renal fascia, perirenal fat, kidneys, perirenal fat, posterior renal fascia and posterior pararenal space.

A critical feature of the renal fascia system is that the posterior renal fascia actually gives rise to the anterior renal fascia and the latero-conal fascia. The posterior renal fascia exists as two laminas that separate into the anterior and latero-conal fascia. As such the posterior renal fascia is also thicker than both the anterior renal fascia and the latero-conal fascia. This gives rise to the anatomical basis for fluid from the anterior pararenal space to enter the flanks, as the fluid can enter the potential space between the two laminas of the posterior renal space where it splits into the anterior renal fascia and latero-conal fascia[32] (figure 4-2).

Posterior Pararenal Space

This space is located between the posterior renal fascia and transversalis fascia. Transversalis fascia attaches to the bodies of the lumbar vertebrae. It is interesting to note that transveralis fascia continues superiorly as endothoracic fascia, which exists between the chest wall and pleura[29,30].

The Lumbar Triangles

The posterior abdominal wall has two potential sites of muscular weakness.

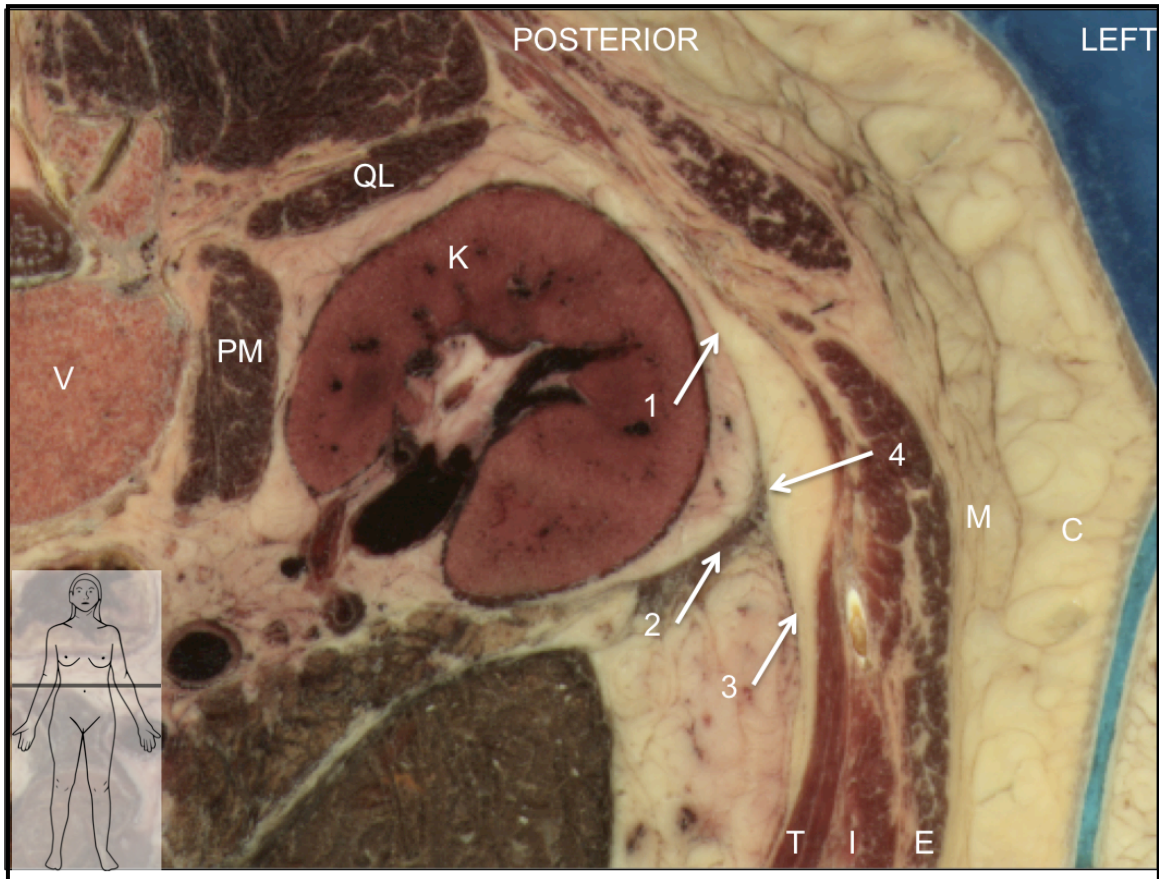

Figure 4-2. Renal fascia system. The posterior renal fascia is composed of two laminas which separate into the anterior renal fascia and the latero-conal fascia. *(1) Posterior renal fascia, (2) Anterior renal fascia, (3) Latero-conal fascia, (4) Junction where Posterior renal fascia splits. (V) Vertebrae (PM) Psoas Major, (QL) Quadratus Lumborum, (K) Left kidney, (M) Membranous layer, (C) Camper's fascia. Image Source: Visible Human Project.*

These areas are often implicated in lumbar hernias[33]. Additionally, these two sites of weakness are potential candidates for a pathway for retroperitoneal fluid to reach the subcutaneous tissue[34].

Superior Triangle of Grynfelt-Lesshaft

The borders of this region of weakness are laterally the internal oblique, medially the quadratus lumborum and superiorly by the 12th rib[33] (figure 4-3).

Inferior Lumbar Triangle of Petit

The borders of this region of weakness are laterally the external oblique, medially the latissimus dorsi and inferiorly the iliac crest. The floor of the triangle is the internal oblique[33].

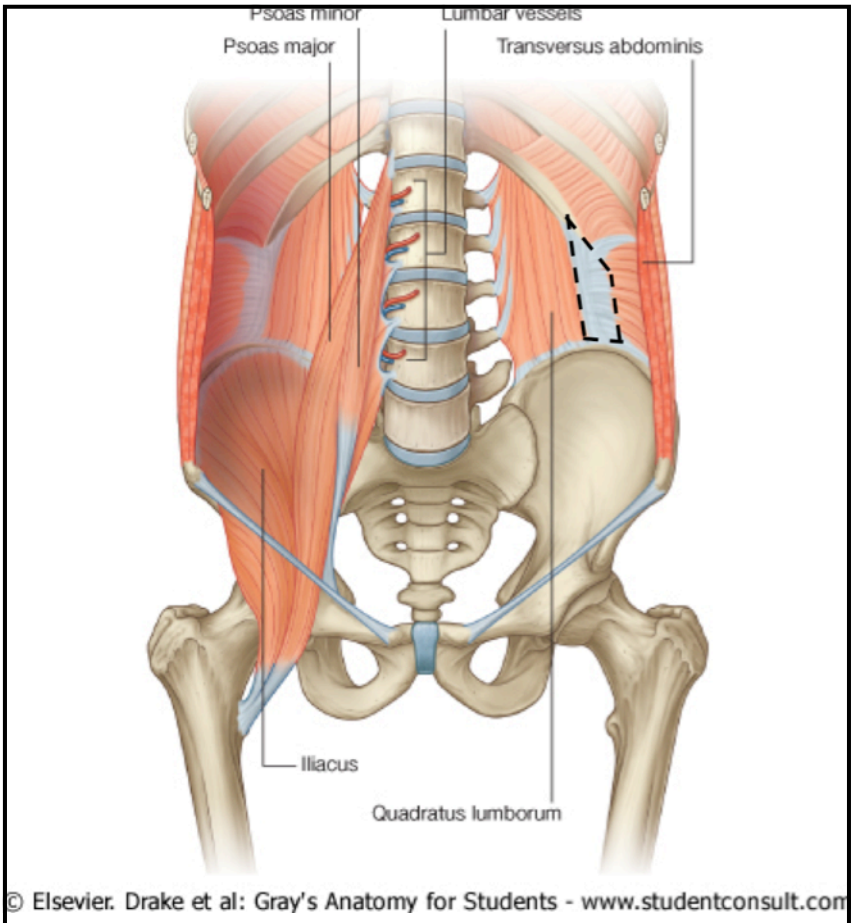

Figure 4-3. Superior triangle of Grynfelt-Lesshaft. Medially bordered by quadratus lamborum, superiorly by the 12th rib and laterally by internal oblique. (*Dashed line) Superior triangle of Grynfelt-Lesshaft. Image Source: Drake et al.*

Cullen's Sign

The manifestation of this sign is attributed to the connection between the retroperitoneum and the peritoneal cavity via the gastrohepatic ligament. The retroperitoneal fluid tracks along the gastrohepatic ligament to enter the peritoneal cavity. The gastrohepatic ligament is continuous with the falciform

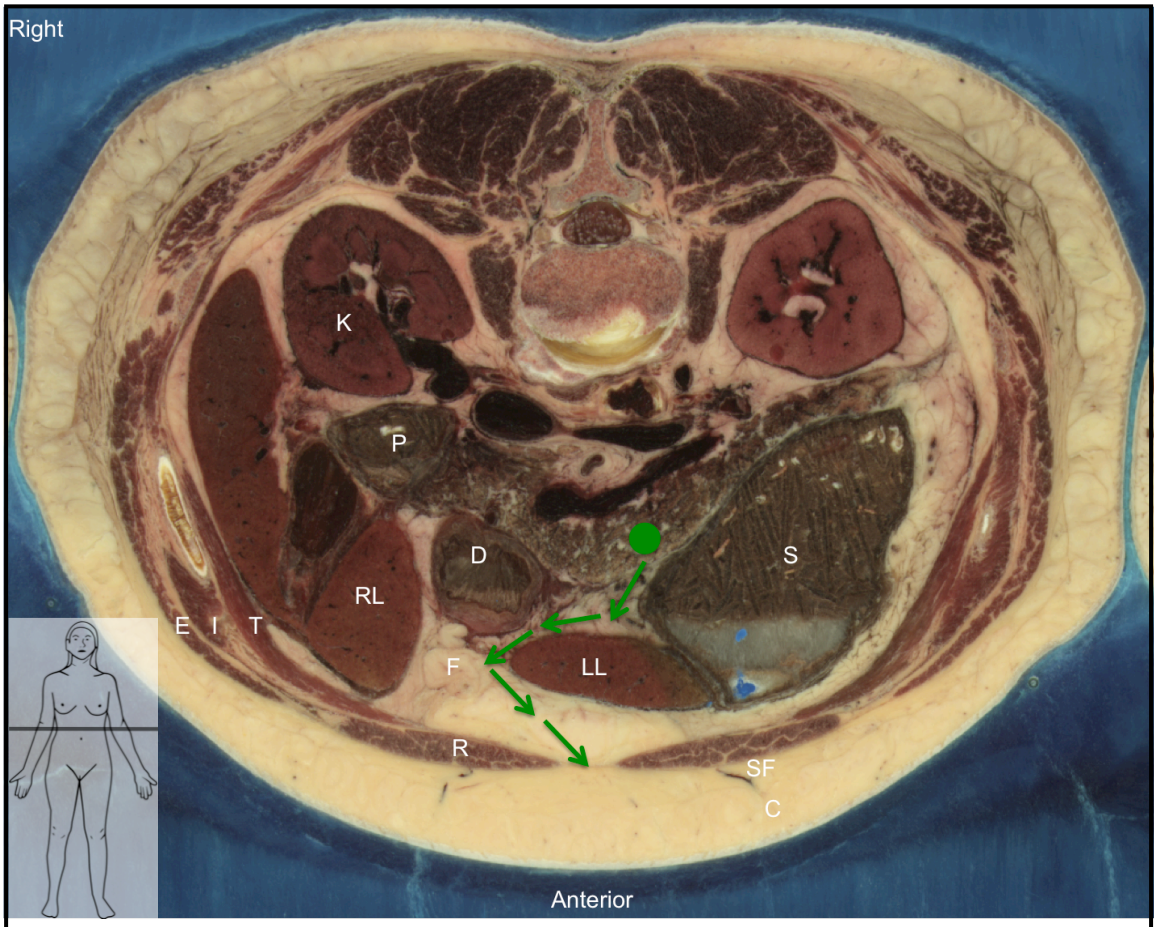

Figure 4-4. The pathway of retroperitoneal fluid for Cullen's sign. Retroperitoneal fluid enters the peritoneal cavity via the gastrohepatic ligament. The gastrohepatic ligament is continuous with the falciform ligament. The falciform ligament travels between the right and left lobe of the liver to enter the umbilicus. *(E) External Oblique. (I) Internal Oblique. (T) Transversus abdominus. (R) Rectus abdominus. (SF) Scarpa's fascia. (C) Camper's fascia. (RL) Right lobe of liver. (D) Duodenum. (LL) Left lobe of liver. (S) Stomach. (P) Pancreas. (K) Right kidney. (F) Fissure for the falciform ligament. (Green dot) Retroperitoneal fluid. (Green arrows) Pathway of the fluid. Image Source: Visible Human Project*

ligament, and as such the fluid continues its travel along this ligament (figure 4-4). The fluid follows the round ligament of the liver (ligamentum teres, part of falciform ligament) traveling into the subcutaneous tissue found deep to the umbilicus[18,34,35,36] . Here the fluid accumulates in the peri-umbilical region but it's extent is limited circumferentially by Scarpa's fascia's attachment to the umbilicus (figure 4-5).

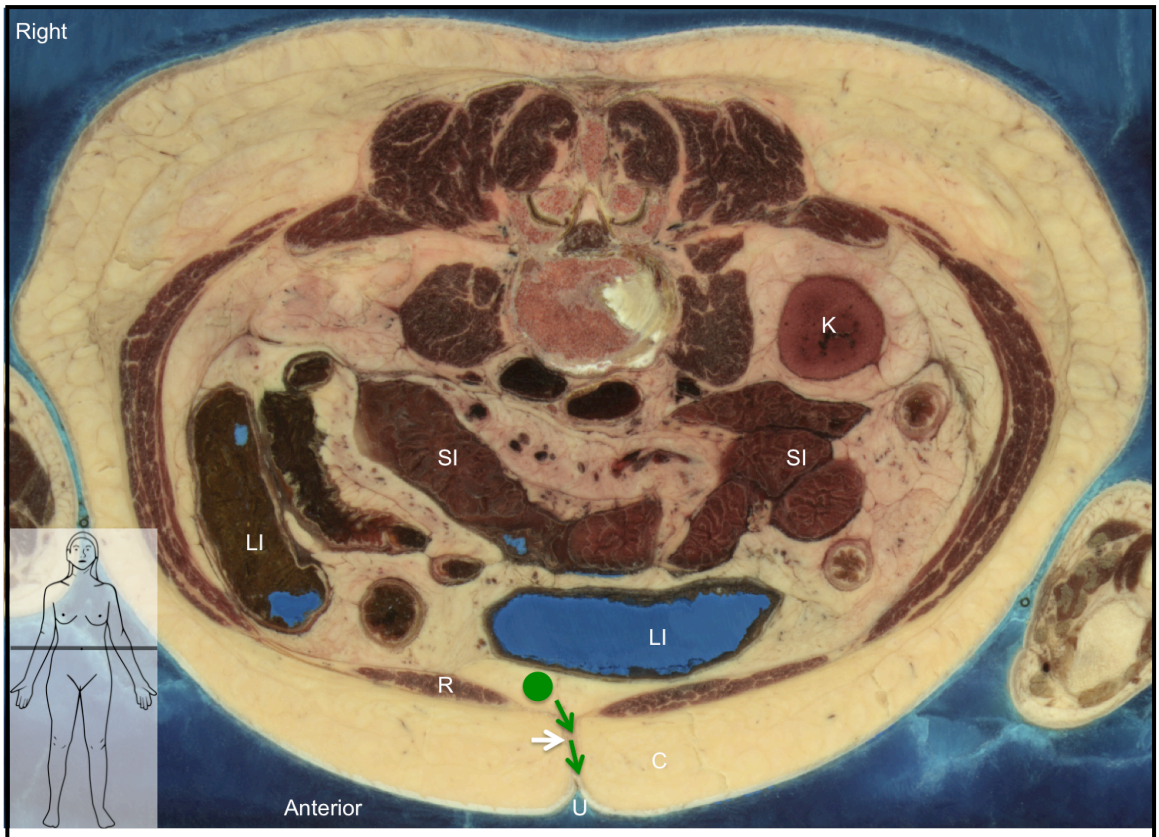

Figure 4-5. The pathway of retroperitoneal fluid for Cullen's sign continued. As the retroperitoneal fluid follows the falciform ligament it reaches the umbilicus where the retroperitoneal fluid is constrained by the attachment of Scarpa's fascia. *(LI) Large intestine. (SI) Small intestine. (K) Left kidney. (R) Rectus abdominus. (U) Umbilicus. (C) Camper's fascia. (White arrow) Scarpa's fascia. (Green dot) Retroperitoneal fluid. (Green arrows) Pathway of fluid. Image Source: Visible Human Project*

Turner's Sign

Turner's sign, like Cullen's sign is also a result of fluid accumulation in the retroperitoneum. With respect to pancreatitis, the pathway for Turner's sign involves the renal fascia. The digestive enzymes damage the pancreatic vessels resulting in hemorrhaging within the anterior pararenal space[34]. This fluid is able to spread into the posterior renal fascia by traveling into the potential space between the two laminas of the posterior renal fascia at the junction where the posterior renal fascia splits into the anterior renal fascia and latero-conal fascia[32,34,36]. The posterior renal fascia blends with the fascia of quadratus lumborum and psoas major. The fluid can thus track along the posterior renal fascia to reach the posterior abdominal muscles. The fluid can then reach the subcutaneous tissue via the superior triangle of Grynfelt-Lesshaft , a site of weakness of the posterior abdominal wall[33,34]. Then the fluid can accumulate into the region created by the membranous layer of superficial fascia loosely attached in the flanks (figure 4-6).

Icterus Marginatus

In order for this sign to manifest, it would require bile to first enter the retroperitoneum to gain access to the subcutaneous tissue. Accumulation of bile in the retroperitoneum has been cited in the literature multiple times usually due to common bile duct injury from surgery or infection[9,22,23].

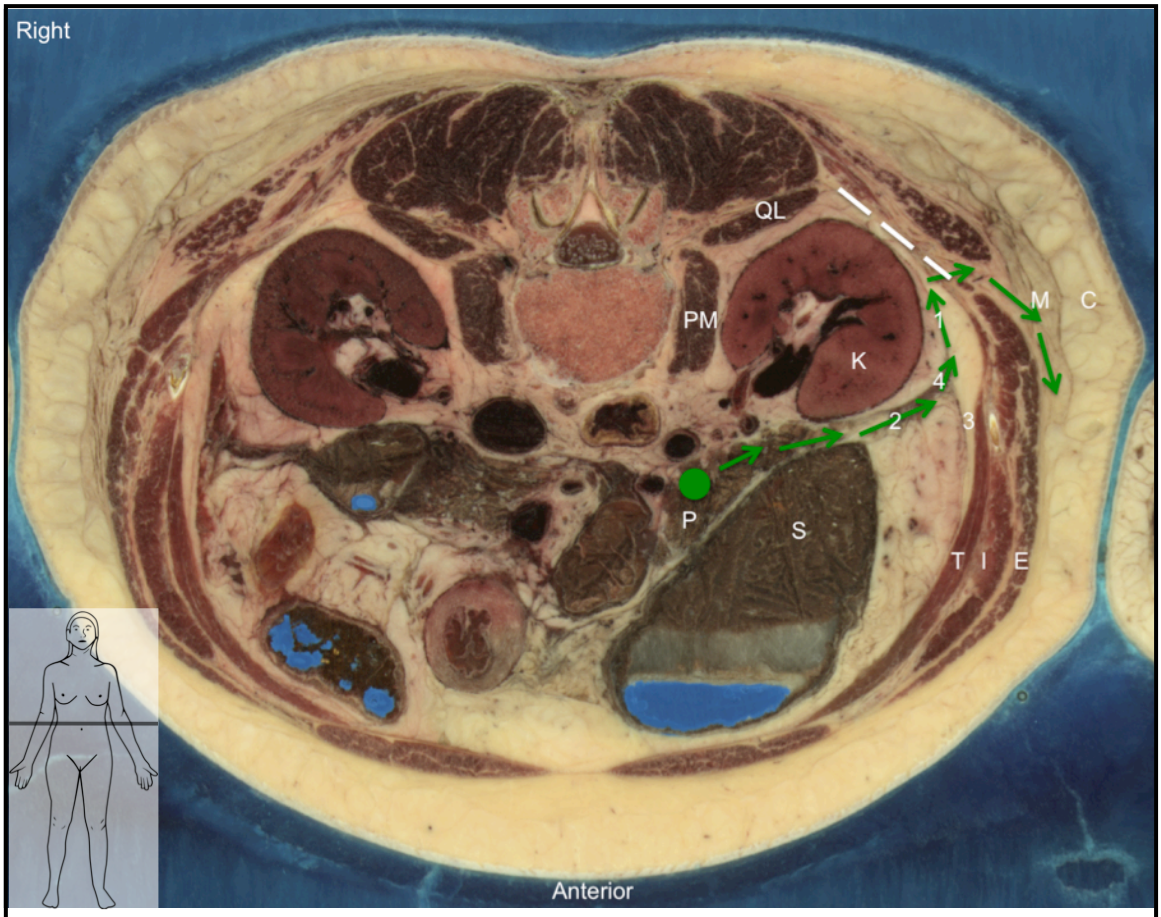

Figure 4-6. The pathway of retroperitoneal fluid for Turner's sign. Retroperitoneal fluid enters the junction where posterior renal fascia splits into anterior renal fascia and latero-conal fascia. *(P) Pancreas. (S) Stomach. (T) Transversus abdominus. (I) Internal Oblique. (E) External Oblique. (PM) Psoas major. (QL) Quadratus lamborum. (K) Left kidney. (M) Membranous layer. (C) Camper's fascia. (Dashed line) Superior Triangle of Grynfelt-Lesshaft. (1) Posterior renal fascia. (2) Anterior renal fascia. (3) Latero-conal fascia. (4) Junction where posterior renal fascia separates into anterior renal and latero-conal fascia. (Green Dot) Retroperitoneal fluid. (Green Arrows) Pathway of the fluid. Image Source: Visible Human Project*

This fluid accumulation can occur due to the connection of the retroperitoneum and peritoneal cavity via the hepatoduodenal ligament. The hepatoduodenal ligament houses the common bile duct which transfers bile from the gall bladder to the duodenum. The distal half of the common bile duct is said to be in the retroperitoneum, specifically in the anterior pararenal space[24]. As such, when a

common bile duct injury occurs, especially in the distal half of the common bile duct, bile can accumulate in the retroperitoneum[23,29,31].

Abdominal wall bile staining along with biliscrotum has been reported in the literature by Neoptolemos et al in 1984. This was attributed to a retroperitoneal perforation after an endoscopic spincterotomy, a procedure used to treat common bile duct stones[9]. In this case a large amount of bile was found in the retroperitoneum as well as in the scrotum. They remarked the similarity of this abdominal bile wall staining to Turner's sign and concluded that such discoloration is a sign of retroperitoneal bile leak[9].

The clinical case presented by Neoptolemos et al is the closest example to the clinical report of "icterus marginatus". The bile staining pattern is the same with respect to the abdominal wall and the scrotum, however their case does not account for the bilateral chest staining seen in the patient for icterus marginatus. The work of Meyers et al presents a plausible pathway for retroperitoneal bile to travel and stain the lateral abdominal wall and potentially accumulate in the loosely attached region of the membranous layer of superficial fascia as described in this study. However, how the bile reached the chest in icterus marginatus remains a mystery. It is possible that a potential communication existed between the flank pocket and the axilla pocket in the patient, thereby the bile was able to travel to the proposed pathway for Turner's sign and then diffuse into the axilla pocket as well. Another possibility is that for this particular patient, the loosely attached region of the membranous layer extended from the flank to the axilla. In

all likelihood it seems that the pathway the retroperitoneal bile took to reach the axilla and chest must have been through the proposed Turner's sign pathway, as there is no other way for the bile to leave the retroperitoneum and reach the axilla and chest. The formation of biliscrotum is attributed to retroperitoneal bile tracking along fascial planes of the retroperitoneum[24]. It is suggested the pathway is provided by the fascial planes of the prevertebral muscles and psoas major. The retroperitoneal bile is subjected to gravity and pressure produced by the muscles, allowing the fluid to enter the deep inguinal ring and enter the scrotum[38].

4.3 Clinical Significance

By demonstrating that Scarpa's fascia is directly responsible for the physical manifestation of the subcutaneous bruising seen in Cullen's sign, contributions can be made to the proposed pathway for its manifestation. Specifically, by proposing Scarpa's fascia's attachment to the umbilicus as the end point for where the retroperitoneal fluid collects, it helps support the established pathway for Cullen's sign. This provides support that the circumferential bruising seen in Cullen's sign is due to a direct structural design and not because of random bruising.

Similarly, by describing a loosely attached region of the membranous layer of superficial fascia in the flanks, the data in this project provide further support for the proposed pathway of Turner's sign. The loosely attached region of the membranous layer in the flank helps explain the physical appearance of Turner's sign. It also takes into account why the bruising is oval in shape and does not

diffuse away from the center. In addition, current anatomical textbooks do not address the possibility of pockets existing in the flanks. The findings in this study suggest additional roles for the membranous layer of superficial fascia, including the formation of pockets in the axilla.

With respect to icterus marginatus the significance of this study are two-fold. The pattern of bile staining seen in the case report for icterus marginatus is the first of its kind in current literature, and represents a novel sign of retroperitoneal bile leakage. Secondly, the demonstration of an area of the membranous layer which was loosely attached in the region of the axilla and chest is a first. This particular area corresponded well to the bile staining seen in the case report for icterus marginatus. Together it makes the case for a new clinical sign of retroperitoneal bile leakage and a possible mechanism for its physical presentation.

4.4 Shortcomings

That being said, it is important to point out a few shortcomings of this study. Perhaps the most important is the sample size. Time was limited as the dissections needed to be complete before the medical students commenced their anatomy laboratories. As a result, the number of cadavers dissected was restricted. In addition, the dissection method was time consuming and meticulous. It involved, as outlined in the materials and methods, removing just the skin from the entire trunk and then removing the underlying fat. However, as experience was gained, the time it took to complete these dissections improved. Nonetheless, the sample size is sufficient to suggest the existence of potential

pockets formed by loosely attached regions of the membranous layer in the flank and the axilla. Furthermore, due to time constraints, the female cadavers were not considered for icterus marginatus dissections. Dissections considering a possibility of a similar arrangement of the membranous layer in female cadavers should be assessed. Indeed, to further make the case for the existence of these pockets, future studies with larger sample sizes need to be performed.

Another point to discuss is that the results were found on embalmed cadavers. Because the bodies were embalmed, the structure and composition compared to a non-embalmed cadaver was different[39]. As a result, how the fascia appears in an embalmed cadaver, maybe different from its appearance in a cadaver that is not embalmed. This may especially be the case with regards to adhesions. In an embalmed cadaver, the pockets created by Scarpa's fascia in the abdomen have weak adhesions. This is likely not the case in a cadaver that is not embalmed. Another consideration is that, due to the fact that these cadavers were used for dissection by medical students, dissections were limited to investigating only one side of the body. Future studies should focus on increased sample size and cadaveric dissection on both embalmed and non-embalmed cadavers.

4.5 Conclusions

The membranous layer of superficial fascia exists throughout the body as demonstrated by Abu-Hijelh et al. In this study, Scarpa's fascia was demonstrated to continue superiorly to the clavicle and laterally to the lateral trunk walls. Scarpa's fascia attaches circumferentially around the umbilicus and this

attachment accounts for the bruising pattern seen in Cullen's sign. The membranous layer in the flanks is loosely attached, creating a pocket. This provides a space for retroperitoneal fluid to accumulate and present the physical pattern seen in Turner's sign. Superiorly in the axilla and chest, there exists another loosely attached region of the membranous layer with adhesions around the nipple. This is a potential space for retroperitoneal bile to accumulate, as seen in icterus marginatus. Using the Visible Human data set, the study was also able to demonstrate similar findings for Cullen's sign and Turner's sign as seen in the dissections. While the membranous layer was identified with respect to icterus marginatus, it was difficult to assess the arrangement of this membranous layer in the chest due to a thinner Camper's fascia.

In summary, the results in this study suggest that the membranous layer of superficial fascia plays a very important role in the physical manifestation of clinical signs associated with retroperitoneal haemorrhaging and bile leakage.

- References -

1. Farzaneh-Far A et al., Cullen's and Turner's Signs. N Engl J Med. 2006; 354:9
2. Fox JA. A diagnostic sign of extraperitoneal haemorrhage. Br J Surg 1966;53:193-5.
3. McAlister VC, Sener A., Demarcated truncal jaundice: a sign of retroperitoneal bile leakage. Ann Intern Med. 2006; 145(1):77
4. Martin BF. The formation of abdomino-perineal sacs by the fasciae of Scarpa and Colles, and their clinical significance. J Anat 1984;138(Pt 4):603-16.
5. A. Scarpa. Sull' ernie: memorie anatomico-chirurgiche. Milano, d. reale Stamperia, 1809; 2nd edition, 1820.
6. Forster DS. A note on Scarpa's fascia. J Anat. 1937 Oct;72(Pt 1):130-1.
7. Cullen TS. A new sign in ruptured extra-uterine pregnancy. American Journal of Obstetric Disorders in Women and Children. 1918;78:457
8. Grey TG, Local discolaration of the abdominal wall as a sign of acute pancreatitis. Br J Surg. 1920;7;394-5
9. Neoptolemos JP et al., Abdominal wall bile staining and 'biliscrotum' after retroperitoneal perforation following endoscopic sphincterotomy. Br J Surg. 1984;71:684
10. Ratzan RM et al. The blue scrotum sign of Bryant: A diagnostic clue to ruptured abdominal aortic aneurysm. J Emerg Med 1987;5:323-9
11. Raw SC., Cullen's sign in perforated duodenal ulcer., Br Med J. 1971 Feb 27;1(5747):505
12. Marinella MA, Baumann M., Cullen's sign associated with metastatic esophageal carcinoma., J Hosp Med. 2008 May;3(3):277-8
13. Chung MA et al. Cullen's sign: it doesn't always mean hemorrhagic pancreatitis. Am J Gastroenterol. 1992 Aug;87(8):1026-8.
14. Sultan A et al. Cullen's sign and massive ovarian enlargement secondary to primary hypothyroidism in a patient with a normal FSH receptor. Arch Dis Child. 2006 Jun;91(6):509-10.
15. Misra A et al. Cullen's sign in amoebic liver abscess. Postgrad Med J. 2002 Jul;78(921):427-8.
16. Chauhan S et al., Cullen's and Turner's sign associated with portal hypertension. Lancet. 2008 Jul 5;372(9632):54.
17. Mabin TA, Gelfand M., Cullen's sign, a feature in liver disease. Br Med J. 1974 Mar 16;1(5906):493-4.
18. Harris S, Naina HV., Cullen's sign revisited. Am J Med. 2008 Aug;121(8):682-3.

19. Sevastianos VA et al., Case 3. Grey-Turner's sign as the first indication of a ruptured hepatocellular carcinoma. J Clin Oncol. 2004 Mar 15;22(6):1156-7.
20. Whipple, C. A case of traumatic rupture of the liver: formation of cystic swelling containing bile stained fluid. *Lancet.* 1898;1:719.
21. Gould L, Patel A., Ultrasound detection of extrahepatic encapsulated bile: "biloma". AJR Am J Roentgenol. 1979 Jun;132(6):1014-5.
22. Colovic, R; Perisic-Savic, M. Retroperitoneal biloma secondary to operative common bile duct injury. *HPB Surgery.* 1991;3(3):193–197.
23. Rastogi R et al., Case report: Retroperitoneal biliary fluid collections secondary to common bile duct rupture - an unusual complication of choledocholithiasis in a child. 2008 Aug;18(3):232-5
24. Brady RR et al., Biliscrotum and retroperitoneal biloma: spontaneous rupture of the biliary system presenting as an incarcerated inguinal hernia. Ulster Med J. 2006 Jan;75(1):85-7.
25. Shigemura K et al., Retroperitoneal abscess perforating into the thoracic cavity in an immunocompromised host. J Infect Chemother. 2008 Aug;14(4):305-7. Epub 2008 Aug 17.
26. Suehiro M et al., Detection of bile leakage into the thoracic cavity by hepatobiliary scintigraphy. Ann Nucl Med. 1991 Nov;5(4):167-9.
27. Worseg AP et al. Scarpa's fascia flap: anatomic studies and clinical application. Plast Reconstr Surg 1997;99:1368 -80
28. Abu-Hijleh MF et al., The membranous layer of superficial fascia: evidence for its widespread distribution in the body. Surg Radiol Anat. 2006;28(6):606-19
29. Feldberg M., Computed tomography of the retroperitoneum: An anatomical and pathological atlas with emphasis on the fascial planes- 1983 - Kluwer Academic Pub
30. Drake R et al. Gray's Anatomy for Students- 2005 – Elsevier Pub
31. Korobkin M et al., CT of the extraperitoneal space: normal anatomy and fluid collections. AJR Am J Roentgenol. 1992 Nov;159(5):933-42.
32. Meyers MA et al., The peritoneal ligaments and mesenteries: pathways of intraabdominal spread of disease. Radiology. 1987 Jun;163(3):593-604.
33. Raptopoulos V et al., Renal fascial pathway: posterior extension of pancreatic effusions within the anterior pararenal space. 1: Radiology. 1986 Feb;158(2):367-74.
34. Armstrong O et al., Lumbar hernia: anatomical basis and clinical aspects. 2008 Nov;30:533-7

35. Meyers MA et al., Grey Turner's sign and Cullen's sign in acute pancreatitis. Gastrointest Radiol. 1989 Winter;14(1):31-7.
36. Bem J et al., Subcutaneous manifestations of severe acute pancreatitis. Pancreas. 1998 May;16(4):551-5.
37. Sugimoto M et al., MPR-hCT imaging of the pancreatic fluid pathway to Grey-Turner's and Cullen's sign in acute pancreatitis. Hepatogastroenterology. 2005 Sep-Oct;52(65):1613-6.
38. Visible Human Project, National Institute of Health
39. Vieira A et al., Letters to the Editor: Biliscrotum as drainage of post-cholecystectomy biloma. Rev Esp Enferm Dig 2008; 100 (8): 515-522
40. Hanzlick R., Embalming, body preparation, burial, and disinterment. An overview for forensic pathologists. Am J Forensic Med Pathol. 1994 Jun;15(2):122-31.
41. Gray H et al., Gray's Anatomy. 1995 – Barnes and Noble Pub
42. Banvard, Richard A., The Visible Human Project® Image Data Set From Inception to Completion and Beyond, Proceedings CODATA 2002: Frontiers of Scientific and Technical Data, Track I-D-2: Medical and Health Data, Montréal, Canada, October, 2002.
43. Gadacz TR, Talamini MA, Lillemoe KD, Yeo CJ., Laparoscopic cholecystectomy. Surg Clin North Am. 1990 Dec;70(6):1249-62