



**Western University**

---

**From the Selected Works of Renjini Lalitha Kumari**

---

2022

# Use of multimodality monitoring to guide clinical care in a non-ventilated neonate with pneumopericardium

Renjini Lalitha Kumari, *Western University*

See discussions, stats, and author profiles for this publication at: <https://www.researchgate.net/publication/365285502>

# Use of multimodality monitoring to guide clinical care in a non-ventilated neonate with pneumopericardium

Article in *BMJ Case Reports* · November 2022

DOI: 10.1136/bcr-2022-251697

CITATIONS

0

READS

13

4 authors, including:



Renjini Lalitha

The University of Western Ontario

10 PUBLICATIONS 4 CITATIONS

SEE PROFILE

# Use of multimodality monitoring to guide clinical care in a non-ventilated neonate with pneumopericardium

Tamara Jahmani, Anne-Marie Tuyisenge, Soume Bhattacharya, Renjini Lalitha

Department of Pediatrics,  
Division of Neonatal-Perinatal  
Medicine, Western University,  
London, Ontario, Canada

## Correspondence to

Dr Soume Bhattacharya;  
Soume.Bhattacharya@lhsc.on.ca

Accepted 25 October 2022

## CASE REPORT

A full-term male infant was born in a tertiary care centre following spontaneous vaginal delivery. The labour was complicated by chorioamnionitis. The infant was born vigorous and neonatal resuscitation was uneventful, with Apgar scores of 5 and 8 at 1 and 5 min, respectively. At 10 min of life the infant developed increased work of breathing in the form of grunting and subcostal retractions. He was started on continuous positive airway pressure (CPAP) set at positive end expiratory pressure 5 cm H<sub>2</sub>O via a T-piece face mask. CPAP was discontinued after 3 min due to lack of any significant improvement. Because of the persistence of respiratory symptoms, the infant was admitted to the intensive care unit (ICU).

On admission to the ICU his respiratory distress had improved. Cardiovascular examination showed muffled heart sounds with capillary refill time of 3 s, a heart rate of 158 beats/min, blood pressure (BP) 55/26(38) mmHg and normal femoral/brachial pulses. Initial capillary blood gas showed mixed acidosis. On chest X-ray, the cardiac shadow was completely surrounded by air with a sharply defined pericardium, suggesting a well-defined pneumopericardium (figure 1), without any evidence of any other coexisting air leaks. Following the diagnosis of pneumopericardium, umbilical venous and arterial catheters were established for more reliable cardiovascular monitoring and support. Low-flow oxygen was initiated at 0.025 L/min at 100% supplemental oxygen to maintain oxygen saturation >92% and for possible nitrogen washout to resolve air leaks.<sup>1-3</sup> Respiratory acidosis markedly improved within 6 hours of life, with maintenance of oxygen saturations between 93% and 100% on low-flow oxygen, but with persistence of metabolic acidosis. The clinical presentation was consistent with isolated non-tension pneumopericardium.

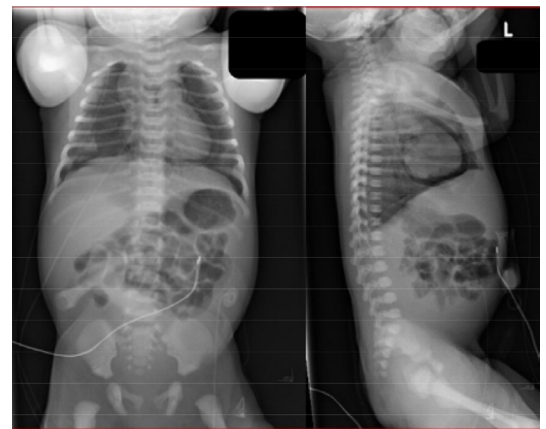
Around 18 hours of life, signs of haemodynamic instability appeared, manifested by episodes of hypotension (systolic BP 46–51 mmHg, diastolic BP 24–29 mmHg, mean BP 33–36 mmHg), with associated pulsus paradoxus, tachypnoea of 61–91/min, mild pallor, raised lactate levels of 5 mmol/L and ongoing metabolic acidosis. A repeat chest X-ray did not show any worsening of the pneumopericardium. In view of concern over tension pneumopericardium, an urgent echocardiogram was performed. Despite technical limitations of echocardiographic imaging due to the air artefact, echocardiography did not show any evidence of cardiac tamponade based on insignificant respiratory variation of 11%

across the mitral valve, 30% across the tricuspid valve and 2% across the aortic and pulmonary valves, along with absence of right ventricular collapse. Conservative management was continued with three normal saline boluses of 10 mL/kg over the next 6 hours, with resultant restoration of normal blood pressures and normalisation of lactate levels. Serial bedside targeted neonatal echocardiography (TNE) scans were performed to assess evolving changes of tamponade, cardiac filling and cardiac output.

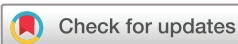The infant was stabilised without any surgical intervention by having vigilant monitoring and assessment of his cardiovascular status using an indwelling arterial line, TNE scans and medical management of his labile cardiovascular status. Low-flow oxygen was discontinued by day of life 4. Subsequent chest X-rays showed gradual reduction in the pneumopericardium over 5 days and he was discharged home after a 7-day stay in the ICU.

## DISCUSSION

Serial TNE assessment was used in this case to assess the exact impact on the cardiac status when clinical and biochemical deterioration occurred. Visualisation of the heart can be challenging in pneumopericardium as air bubbles are a poor conductor of sound waves, leading to its significant reflection, affecting image quality. Echocardiographic diagnosis for cardiac tamponade in general includes assessment of cardiac chamber collapsibility, respiratory variation in the mitral (>25% drop in mitral peak E-wave during inspiration compared with



**Figure 1** Chest X-ray anteroposterior and lateral views showing a sharply defined pericardium surrounding a layer of air around the cardiac shadow and the extent of pneumopericardium.



© BMJ Publishing Group Limited 2022. No commercial re-use. See rights and permissions. Published by BMJ.

**To cite:** Jahmani T, Tuyisenge A-M, Bhattacharya S, et al. *BMJ Case Rep* 2022;**15**:e251697. doi:10.1136/bcr-2022-251697

## Images in...

expiration) and tricuspid inflows (>40% drop in tricuspid peak E-wave in expiration in comparison to inspiration), variation in ventricular output during the respiratory cycle (>10% drop in peak velocity seen in the aorta in inspiration and >10% increase in the peak velocity seen in the pulmonary outflow in inspiration), inferior vena cava collapsibility (<50% during respiration) and paradoxical movement of the interventricular septum during diastole.<sup>4</sup> Partial disappearance of the cardiac image during systole and comet tail artefacts emerging from the pericardium are more specific echocardiographic signs for pneumopericardium.<sup>5</sup> Serial monitoring with echocardiography for development of collapsibility of cardiac cavities, starting with the right atrium followed by the right ventricle and left atrium, a worsening trend in the respiratory variation across the inflow and outflow valves and increasing distension of the inferior vena cava will indicate echocardiographic progression towards cardiac tamponade.

## Learning points

- ▶ This case shows the progressive evolution of an initially non-tension pneumopericardium and highlights the necessity of multimodality monitoring of combining imaging modalities with vigilant clinical/biochemical monitoring.
- ▶ Serial TNE scans were used to assess whether the deterioration in the infant's clinical and biochemical parameters in a previously non-tension pneumopericardium was due to the development of cardiac tamponade, thereby guiding appropriate management in terms of continuing with a conservative approach versus the need for urgent invasive procedural intervention.
- ▶ Air (mostly nitrogen and oxygen) are poorly absorbed by the pericardium, unlike the connective tissues of the mediastinum, hence the slower resolution of pneumopericardium despite the attempt at nitrogen wash.

Traditionally, isolated asymptomatic pneumopericardium is managed conservatively with supportive measures and close clinical monitoring of cardiovascular status, while tension pneumopericardium requires urgent procedural intervention with needle thoracentesis, even without loss of clinical haemodynamic stability.<sup>3</sup> With increasing access to TNE services, serial TNE scans can be a valuable tool to assess echocardiographic signs of tamponade in the event of clinical deterioration, potentially providing guidance in therapeutic management. There could be room for conservative management and vigilant observation with serial TNE scans when there is an absence of echocardiographic evidence of cardiac tamponade, despite clinical signs suggestive of it.

**Twitter** Tamara Jahmani @Tamara Jahmani

**Contributors** TJ: drafted the case report and formatted the images to a specified guideline. A-MT: drafted the case report. SB and RL: critical revision of the drafts and approval for submission.

**Funding** The authors have not declared a specific grant for this research from any funding agency in the public, commercial or not-for-profit sectors.

**Competing interests** None declared.

**Patient consent for publication** Consent obtained from parent(s)/guardian(s)

**Provenance and peer review** Not commissioned; externally peer reviewed.

Case reports provide a valuable learning resource for the scientific community and can indicate areas of interest for future research. They should not be used in isolation to guide treatment choices or public health policy.

## REFERENCES

- 1 Hummler HD, Bandstra ES, Abdenour GE. Neonatal fellowship. Neonatal pneumopericardium: successful treatment with nitrogen washout technique. *J Perinatol* 1996;16:490–3.
- 2 Lawson EE, Gould JB, Tausch HW, . Neonatal pneumopericardium: current management. *J Pediatr Surg* 1980;15:181–5.
- 3 Bonardi CM, Spadini S, Fazio PC, *et al*. Nontraumatic tension pneumopericardium in nonventilated pediatric patients: a review. *J Card Surg* 2019;34:829–36.
- 4 Pérez-Casares A, Cesar S, Brunet-Garcia L, *et al*. Echocardiographic evaluation of pericardial effusion and cardiac tamponade. *Front Pediatr* 2017;5:79.
- 5 Bobbia X, Claret PG, Muller L, *et al*. Pneumopericardium diagnosis by point-of-care ultrasonography. *J Clin Ultrasound* 2013;41:235–7.

Copyright 2022 BMJ Publishing Group. All rights reserved. For permission to reuse any of this content visit <https://www.bmj.com/company/products-services/rights-and-licensing/permissions/>  
BMJ Case Report Fellows may re-use this article for personal use and teaching without any further permission.

Become a Fellow of BMJ Case Reports today and you can:

- ▶ Submit as many cases as you like
- ▶ Enjoy fast sympathetic peer review and rapid publication of accepted articles
- ▶ Access all the published articles
- ▶ Re-use any of the published material for personal use and teaching without further permission

### Customer Service

If you have any further queries about your subscription, please contact our customer services team on +44 (0) 207111 1105 or via email at [support@bmj.com](mailto:support@bmj.com).

Visit [casereports.bmj.com](http://casereports.bmj.com) for more articles like this and to become a Fellow