

University of Dayton

From the Selected Works of Philip A. Anloague

Winter December, 2009

**Anatomical Variations of the Lumbar
Plexus: A Descriptive Anatomy
Study with Proposed Clinical
Implications.pdf**

Philip A. Anloague

Anatomical Variations of the Lumbar Plexus: A Descriptive Anatomy Study with Proposed Clinical Implications

PHILIP A. ANLOAGUE, PT, DHSc, OCS, MTC¹; PETER HUIJBREGTS, PT, DPT, OCS, FAAOMPT, FCAMT²

Evidence-based practice emphasizes the examination and application of evidence from clinical research into diagnosis, prognosis, and outcomes based on a formal set of rules¹. One method of evaluating evidence is to assign levels of evidence². In this evidence hierarchy, extrapolations from basic science research are classified as the lowest level of evidence. However, especially in situations where higher-level research evidence is insufficient, such extrapolation based on a thorough knowledge of relevant anatomy often still serves to guide clinical reasoning. This importance of anatomy remains recognized within physical therapy education in the United States, both as part of program entrance requirements³ and as a part of

the required basic sciences content in entry-level curricular content⁴. In those circumstances where clinical diagnosis is solely based on anatomical extrapolation, knowledge of anatomical deviations with a potential impact on interpretation of test results becomes even more important.

The lumbar plexus originates from the ventral rami of the L1–L4 nerve roots and projects laterally and caudally from the intervertebral foramina, posterior to the psoas major muscle. A communicating branch from the T12, also known as the subcostal nerve, often joins the first lumbar nerve^{5–10}. The L2–L4 ventral rami first bifurcate into an anterior and posterior primary division. The T12 and L1 nerves and the L2–L4 anterior primary

divisions supply muscular branches to the psoas major and quadratus lumborum. Both primary divisions then enter the lumbar plexus and give rise to six peripheral nerves. Within this plexus, the L1 nerve splits into a cranial and caudal branch. The cranial branch bifurcates into the iliohypogastric and ilioinguinal nerves, the former also formed by the subcostal nerve in people where this nerve contributes to the lumbar plexus. The caudal branch of the L1 nerve unites with the anterior division of the L2 nerve to form the genitofemoral nerve. The anterior divisions of the L2–L4 roots form the obturator nerve. The lateral femoral cutaneous nerve arises from the posterior divisions of the L2 and L3 roots; the posterior divisions of L2, L3, and L4 join to create the femoral nerve (Figure 1). Table 1 presents a summary of the normal presentation of nerves of the lumbar plexus based upon a review of several authoritative anatomical texts commonly used in physical therapy education^{5–10}.

The purpose of this study was to describe the anatomical variations in the lumbar plexus from the origin at the ventral roots of (T12) L1–L4 to the exit from the pelvic cavity based on our descriptive anatomy study of human cadavers as compared to the above description of normal anatomy^{5–10}. Comparing our findings to anatomical variation described elsewhere in the literature, we will also suggest possible clinical implications

ABSTRACT: This study used dissection of 34 lumbar plexes to look at the prevalence of anatomical variations in the lumbar plexus and the six peripheral branches from the origin at the ventral roots of (T12) L1–L4 to the exit from the pelvic cavity. Prevalence of anatomical variation in the individual nerves ranged from 8.8–47.1% with a mean prevalence of 20.1%. Anatomical variations included absence of the iliohypogastric nerve, an early split of the genitofemoral nerve into genital and femoral branches, an aberrant segmental origin for the lateral femoral cutaneous nerve, bifurcation of the lateral femoral nerve prior to exiting the pelvic cavity, bifurcation of the femoral nerve into two to three slips separated by psoas major muscle fibers, the presence of a single anterior femoral cutaneous nerve rather than the normal presentation of two separate anterior femoral cutaneous branches, and the presence of an accessory obturator nerve. Comparison with relevant research literature showed a wide variation in reported prevalence of the anatomical variations noted in this study. Clinical implications and directions for future research are proposed.

KEYWORDS: Anatomical Variation, Clinical Implications, Lumbar Plexus

¹Program Director, Doctor of Physical Therapy Program, University of Dayton

²Assistant Professor, Online Education, University of St. Augustine for Health Sciences

Address all correspondence and request for reprints to: Philip A. Anloague, anloague@udayton.edu

TABLE 1. Lumbar plexus: Normal anatomy.

Nerve	Origin (Ventral Rami)	Course and Function
Iliohypogastric	L1	Emerges from the superior aspect of the lateral margin of the psoas major ⁶ ; enters the abdomen posterior to the medial arcuate ligaments and courses inferiolaterally along the anterior surface of the quadratus lumborum ⁵⁻¹⁰ , then pierces and innervates the posterior fibers of the transverse abdominis near the iliac crest and traverses through the internal and external oblique abdominis muscles to which it supplies motor branches. Superficial innervation is supplied to the skin of the gluteal region posterior to the lateral cutaneous branch of T12 via a lateral cutaneous branch. The anterior cutaneous branch of the iliohypogastric nerve innervates the skin of the hypogastric region ⁵⁻¹⁰ .
Ilioinguinal	L1	Runs caudal to the iliohypogastric nerve; pierces and innervates the transverse abdominis near the anterior part of the iliac crest, communicates with the iliohypogastric, then supplies motor branches to the internal oblique abdominis. Follows the spermatic cord through the superficial inguinal ring and terminates superficially over the proximal and medial aspect of the thigh, the root of the penis and the scrotum, or mons pubis and labia majora ⁵⁻¹⁰ .
Lateral Femoral Cutaneous	Posterior Division L2–L3	Travels obliquely across the iliacus muscle in the direction of the anterior superior iliac spine. Passes beneath the inguinal ligament and divides into an anterior and posterior branch. The anterior branch supplies the skin on the anterolateral aspect of the thigh. The distal branches communicate with the anterior cutaneous filaments of the femoral nerve and its infrapatellar branches of the saphenous nerve to form the patellar plexus. The posterior branch pierces the fascia lata and supplies the skin of the lateral thigh from greater trochanter to mid-thigh ⁵⁻¹⁰ .
Femoral	Posterior Division L2–L4	Primary nerve innervating the anterior aspect of the thigh and the largest of the peripheral branches of the lumbar plexus. It emerges through the psoas major fibers and passes down between the psoas major and the iliacus, then passes underneath the inguinal ligament just lateral to the femoral artery as it enters the thigh. Within the abdomen, the femoral nerve gives off muscular branches to the iliacus. Peripherally, there are two large anterior cutaneous branches (intermediate and medial cutaneous nerves). The intermediate cutaneous branch descends along the anterior thigh to supply the skin and then contributes to the patellar plexus. The medial cutaneous branch supplies the skin on the medial side of the thigh. The femoral nerve sends several terminal branches including the nerve to pectineus, nerve to vastus medialis obliquus, nerve to sartorius, and the saphenous nerve ⁵⁻¹⁰ .
Genitofemoral	L1–L2	Penetrates the substance of the psoas major and runs inferiorly along the anterior aspect of the muscle belly beneath the transversalis fascia and the peritoneum, then bifurcates into a genital and femoral branch. The genital branch passes through the transverse and spermatic fascia, traverses the internal inguinal ring and then reaches the spermatic cord. Lying on the dorsal aspect of the cord, this nerve supplies the cremaster muscle and the skin of the scrotum and thigh. In females, the genital nerve accompanies the round ligament of the uterus. The femoral branch travels beneath the inguinal ligament alongside the external iliac artery. After entering the femoral sheath superficial and lateral to the femoral artery, the femoral branch exits the sheath and fascia lata to supply the skin of the proximal anterior thigh ⁵⁻¹⁰ .
Obturator	Anterior L2–L4 Division	Emerging from the medial border of the psoas major beneath the common iliac vessels, this nerve travels along the lateral wall of the lesser pelvis and enters the obturator foramen. After entering the thigh, it bifurcates into an anterior and posterior branch. The anterior branch passes anterior to the obturator externus, deep to the pectineus and adductor longus, and superficial to the adductor brevis. Muscular branches are supplied to the adductor longus, gracilis, and adductor brevis. The posterior branch of the obturator nerve exits the anterior aspect of the obturator externus, travels beneath the adductor brevis anterior to the adductor magnus, and then gives off muscular and articular branches. The muscular branches innervate the obturator externus, adductor magnus, and the adductor brevis ⁵⁻¹⁰ .

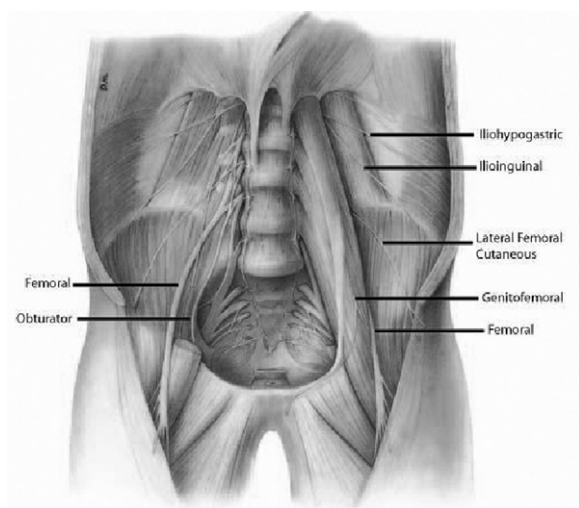


FIGURE 1. Lumbar plexus with surrounding musculature: Normal anatomy

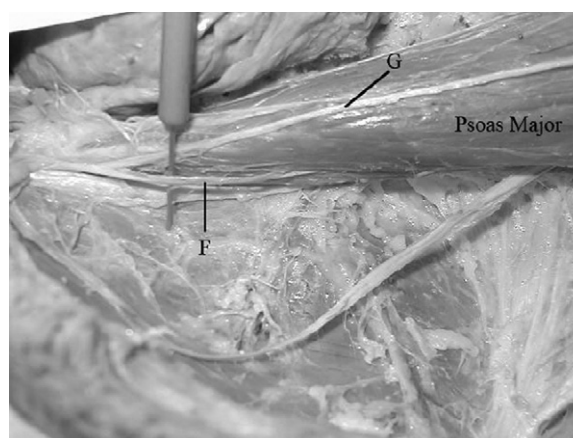


FIGURE 2. Variation of the genitofemoral nerve. The genitofemoral nerve has prematurely bifurcated into two components, the genital branch (G) and femoral branch (F). Fibers of the psoas major lie between these branches.

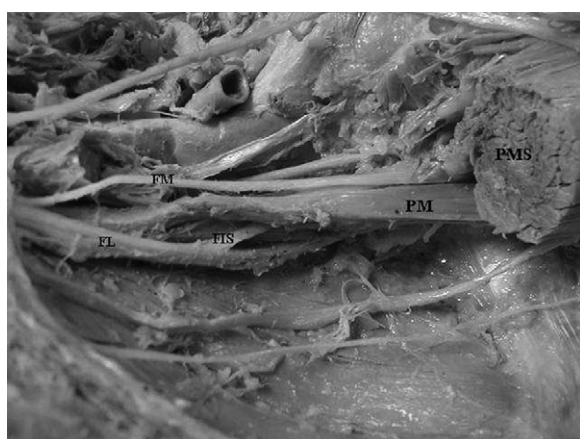


FIGURE 3. Variation of the femoral nerve. *Cadaver 8 Left.* The psoas major is sectioned (PMS) to reveal the bifurcation of the femoral nerve into medial and lateral segments (FM & FL) with an interconnecting segment (FIS). There are fibers of the psoas major (PM) traversing between this nerve plexus.

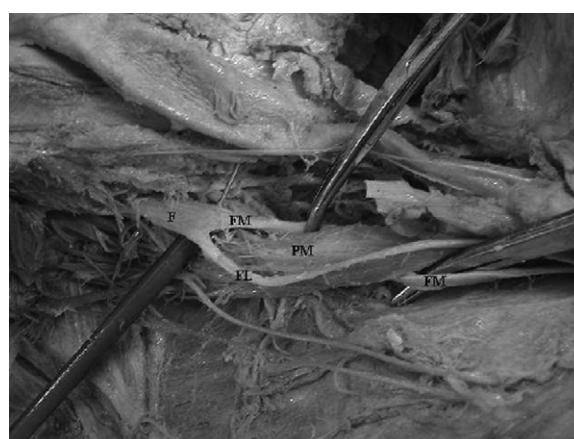

FIGURE 4. Variation of the femoral nerve. *Cadaver #10 Right.* The femoral nerve (F) bifurcates into a medial (FM) and lateral (FL) segment. The lateral segment travels posterior to the PM proper (PM), exits along the lateral border, and then rejoins the medial segment.

with regard to diagnosis of anatomical variations of the lumbar plexus.

Materials and Methods

Cadavers

We initially included 19 human cadavers (38 unilateral lumbar plexes) from the Andrews University Master of Physical Therapy program in this study.

There were 10 male and 9 female cadavers; average age at time of death was 75.1 years. Specimens were excluded if there was evidence of surgical intervention involving the abdomen, lumbar spine, or lumbar plexus to rule out iatrogenic anatomical deviations. Of the proposed cadavers, two were excluded due to evidence of an abdominal surgical intervention leaving 17 (with 34 plexes) that were appropriate for this study.

Dissection

The primary author dissected all cadavers. As a professor of graduate-level gross anatomy, at the time of this study this author had 10 years of experience in cadaveric dissection. The descriptive study presented here was part of the graduation requirements for an advanced-level doctorate in physical therapy centered on a focused study of the

TABLE 2. Percent variation of the lumbar plexus.

Nerve	Number of Variations N=34	Percent Variation N=34	Unilateral Variation	Bilateral Variation	Female N=9	Male N=8
Lumbar Plexus	30	88%			88.8%	87.5%
Iliohypogastric	7	20.58%	25%	75%	50%	50%
Ilioinguinal	0	0.0%	-	-	-	-
Lateral Femoral Cutaneous	6	17.64%	50%	50%	50%	50%
Femoral	12	35.29%	67%	33%	44.4%	55.55%
Genitofemoral	16	47.05%	58%	42%	50%	50%
Obturator	0	0.0%	-	-	-	-

functional anatomy of the lumbar spine. The nerves of the lumbar plexus were tracked from the lumbar roots through to their exit from the pelvic cavity (Figures 1–4). The results were described narratively with descriptive statistics and recorded with digital photography.

Data Analysis

Data analysis was limited to descriptive statistics. The prevalence of variation was calculated for each of the six nerves derived from the lumbar plexus and for all structures combined. To allow for a summary impression of the likelihood that a clinician might encounter anatomical variation in the lumbar plexus and its peripheral nerves, we also calculated a mean prevalence and standard deviation (SD) with regard to the presence of anatomical variation.

Results

Anatomical variation of the lumbar plexus (including the six peripheral nerves originating from this plexus) was noted in 15 of the 17 (88%) cadavers dissected. The percentage of variation of each nerve was calculated and is presented in Table 2. Overall, 41 of 204 nerves studied showed variations. The mean prevalence of anatomical varia-

tion was 20.1% (SD 18.8%). Variations were found most frequently in the femoral, iliohypogastric, lateral femoral cutaneous, and genitofemoral nerves (Table 2).

Iliohypogastric and Ilioinguinal Nerves

Seven of the 34 (20.6%) investigated lumbar plexes demonstrated the absence of the iliohypogastric nerve. There were no apparent variations noted in the ilioinguinal nerve although we should note that in two of the cadavers, the ilioinguinal and iliohypogastric nerves were conjoined as they exited through the substance of the psoas major musculature. Normally, these nerves bifurcate from the cranial branch of L1 and course independently after traversing the psoas major. While this presentation was not considered variant in that it is unlikely to have any clinical impact, in these two cadavers, the nerves remained contained within a common epineurium lateral to the psoas major.

Genitofemoral Nerve

It was observed that 16 of the 34 (47.1%) lumbar plexes demonstrated a variation of the genitofemoral nerve complex (Table 2). Typically, this nerve bifurcates

into its terminal genital and femoral branches midway along the anterior surface of the psoas major. The most common variation occurred in 9 of 34 plexes (26.5%) and included a split of the genitofemoral nerve into the genital and femoral branches within the substance of the psoas muscle with fibers of the psoas major passing between these branches (Figure 2). Seven variant genitofemoral nerves (20.6%) had this bifurcation occur at the upper rather than mid-portion of the anterior surface of the psoas.

Lateral Femoral Cutaneous Nerve

Six of the 34 plexes (17.6%) demonstrated variation in the lateral femoral cutaneous nerve. Whereas the lateral femoral cutaneous nerve normally arises from the posterior divisions of the L2 and L3 roots, in 4 lumbar plexes, the lateral femoral cutaneous nerve arose from the L1 and L2 nerve roots and in one plexus it had its origin solely from the L2 nerve. Another variation included a bifurcation of the lateral femoral nerve within the pelvic cavity prior to its exit near the anterior superior iliac spine; such bifurcations normally occur after the nerve exits the pelvis.

Femoral Nerve

The femoral nerve was found to vary in 12 (35.3%) of the investigated lumbar plexes. In these 12 plexes, the femoral nerve was observed to bifurcate into two and sometimes three separate slips; in most cadavers, this process occurred within the mid-substance of the psoas major (Figures 3–4). These slips were separated by the muscle fibers of the psoas major before they rejoined prior to the femoral nerve exiting from the pelvic cavity as it passed beneath the inguinal ligament. One cadaver presented with a medial and lateral bifurcation of the nerve with psoas major musculature passing between with an intermediate connection between the two nerve slips before a more distal rejoining of the nerve segments (Figure 3). A single anterior femoral cutaneous nerve rather than the normal presentation of two

separate anterior femoral cutaneous branches⁵ was present in one of the cadavers (2.9%) with the anatomical variation described above, thereby not altering the overall prevalence of anatomical variation of 35.3%.

Obturator Nerve

No apparent variations were noted in the obturator nerve proper. However, an accessory obturator nerve, a small nerve arising from the primary anterior divisions of the L3 and L4 nerves that follows along the medial border of the psoas major muscle and then exits over the superior ramus of the pubic bone rather than through the obturator foramen with the obturator nerve to the innervate the pectineus muscle and the hip joint⁵ was found in 8.8% of the plexes.

Discussion

This study looked at the prevalence of anatomical variations in the lumbar plexus and the six peripheral branches from the origin at the ventral roots of (T12) L1–L4 to the exit from the pelvic cavity. Because reported prevalence is important in estimating the likelihood that we may be dealing with a patient with anatomical variation, it is relevant to place this study in context by reviewing other research into prevalence of such anatomical variation. Taking into account the rather high mean prevalence of 20.1% (SD 18.8%) of such variation reported in this study and the clinical impact that this variation may have in those instances when clinicians are forced to base their clinical diagnostic reasoning solely on extrapolation from anatomical knowledge, we also propose clinical implications of the variations noted in this study.

Comparison with Relevant Reported Prevalence

We performed a literature search for basic science studies and case reports limited to English-language references only using the PubMed, CINAHL, Ohio

LINK, PEDro, APTA Hooked on Evidence, and BIOSIS databases from database inception until April 2009 using the following search terms: *lumbar plexus, anatomical variation, iliohypogastric nerve, ilioinguinal nerve, femoral nerve, lateral femoral cutaneous nerve, obturator nerve, and genitofemoral nerve.*

In the current study, 20.6% of the lumbar plexes had no iliohypogastric nerve. Our literature search strategy yielded no references with regard to anatomical variation of the ilioinguinal and iliohypogastric nerves. *Gray's Anatomy*⁵ noted that the iliohypogastric or ilioinguinal nerves may or may not arise from a common trunk or that these nerves may communicate at the iliac crest. In the event that the nerves join at the iliac crest, the iliohypogastric typically is reported to supply the missing ilioinguinal branches. *Gray's Anatomy*⁵ also reported that the ilioinguinal nerve may be absent with compensation via the genital branch of the genitofemoral nerve. Likewise, the genital branch may be absent with the ilioinguinal nerve substituting for it. No data on prevalence of these reported anomalies were provided.

Specific to the genitofemoral nerve and similar to the current study, Sim and Webb¹¹ also found that the nerve at times divided into genital and femoral branches prior to emergence from the psoas major. In contrast to the prevalence of 26.5% for this variation established in the current study, they noted early division in only 5 (8.3%) of 60 plexes.

Generally described as arising from the posterior divisions of the L2 and L3 roots, in the current study the lateral femoral cutaneous nerve arose in 4 plexes (11.8%) from the L1 and L2 nerve roots and in one plexus it had its origin solely from the L2 nerve (2.9%), leading to a cumulative variation in segmental contribution to the nerve of 14.7%. Reporting prevalence for cadavers but not plexes, De Ridder, De Lange, and Popta¹² reported that in 24 of 200 cadavers, the lateral femoral cutaneous nerve arose from the L1 and L2, and even solely from the second or third lumbar nerve. Sim and Webb¹¹ reported that in 22 (36.7%) of 60 plexes, the lateral femoral cutane-

ous nerve arose from the first two lumbar nerves; in one plexus (1.7%), the nerve arose solely from the second lumbar ventral ramus and in 6 plexes (10%), it derived directly from the femoral nerve, making for a total of 48.3% variation for the lateral femoral cutaneous nerve. Erbil, Oderoğlu, and Başar¹³ reported on a patient where the right lateral femoral cutaneous nerve was derived from the anterior divisions of the first and second lumbar nerve roots. Webber¹⁴ noted eight distinct patterns of neural contribution to the lateral femoral cutaneous nerve in 50 plexes.

In the current study, we found one (2.9%) bifurcation of the lateral cutaneous femoral nerve within the pelvic cavity prior to its exit near the anterior superior iliac spine in 34 plexes but no other abnormalities were noted in this region. Reporting prevalence in cadavers but not plexes, Grothaus et al¹⁵ found that in 27.6% of the 29 cadavers, the lateral femoral cutaneous nerve bifurcated into additional branches before crossing the inguinal ligament. Erbil et al¹⁶ reported similar bifurcations of this nerve into either two or three branches in two (3.5%) of 56 plexes. Not reporting on plexes but rather on dissection findings in 53 cadavers, Rosenberger, Loeweneck, and Meyer¹⁷ found that in 23% the lateral femoral cutaneous nerve gave rise to two branches. Carai et al¹⁸ also reported early nerve bifurcation but also noted that the lateral femoral cutaneous nerve was wholly absent in 13 (8.8%) of 148 patients who received surgical intervention for meralgia paraesthetica.

In the current study, in 12 plexes (35.3%), the femoral nerve bifurcated into two or three separate slips mostly within the mid-substance of the psoas major. Spratt, Logan, and Abrahams¹⁹ reported that 3 of 136 plexes (2.2%) contained a variant slip of the iliacus and psoas major muscles that split the femoral nerve. In a case report, Jelev, Shivarov, and Surchev²⁰ detailed similar muscular variations of the iliacus and psoas muscles splitting the femoral nerve. Jakubowicz²¹ investigated the topography of the femoral nerve in relation to components of the iliopsoas muscle in 60 human fetuses. In 3 (2.5%) of 120

plexes, a separate band of the lateral fibers of the psoas major passed between the trunks of the femoral nerve. In 3 further plexes, muscular fibers of the iliacus traversed between the trunks of the fetal femoral nerve leading to a prevalence of 5% for interactions between the ilio-psoas muscle and the femoral nerve similar to the ones reported in the current study.

In the current study, we found an accessory obturator nerve in 8.8% of the plexes. Akkaya et al²² reported the accessory obturator nerve in 3 (12.5%) of 24 lumbar plexes. Sim and Webb¹¹ identified the accessory obturator nerve in 7 of 60 plexes (11.6%), noting that it occurred more frequently on the left side and in females. Webber¹⁴ found accessory obturator nerves in 4 (8%) of 50 lumbar plexes. In contrast, Tubbs et al²³ reported finding not a single accessory obturator nerve in 22 plexes.

In summary, prevalence reported in the literature for anatomical variations of the lumbar plexus from the origin at the ventral roots of (T12) L1–L4 to the exit from the pelvic cavity varies widely and, this variance does not allow for the extrapolation of clear data on pretest probability that such a variation might be present in the patient presenting to our clinic. In addition, with some studies reporting on cadavers and others on plexes, comparison between studies is not always possible.

Clinical Implications

Although, as noted above, the literature does not allow for extrapolation of clear data on pretest probability with regard to the presence of anatomical variation in our patients, findings in the current study lead us to propose a number of other possible clinical implications.

The iliohypogastric nerve provides sensory innervation to the suprapubic region and it provides a lateral cutaneous branch that crosses over the iliac crest to innervate the upper lateral buttock. The ilioinguinal nerve provides sensory innervation to skin over the inguinal ligament, the upper medial thigh, and the mons pubis or base of the penis. The femoral branch of the genitofemoral nerve supplies the skin over the femoral

triangle and its genital branch innervates the skin of the scrotum or labia²⁴. Absence of a separate iliohypogastric nerve likely results in the ilioinguinal and, as *Gray's Anatomy*⁵ noted, the genitofemoral nerve taking over its function. The only scenario where the absence of the iliohypogastric nerve may become diagnostically relevant is when a peripheral neuropathy affecting the ilioinguinal nerve leads to sensory abnormalities in both the inguinal and iliohypogastric areas, leading the clinician to assume a possible L1 radiculopathy rather than a peripheral compression neuropathy of the ilioinguinal nerve in, for example, the inguinal canal. Absence of the iliohypogastric nerve may also have implications for the likelihood and presentation of nerve damage in this region during surgical procedures such as inguinal herniotomy. The observed variation in the location of branching in the genitofemoral nerve would seem to be of little clinical utility.

In our current study, the lateral femoral cutaneous nerve derived its segmental innervation from segments other than L2 and L3 in 14.7% of plexes. Although, with its multi-segmental innervation from most commonly L2 and L3 and less commonly L1 and L2, the differentiation between radiculopathy and peripheral neuropathy affecting the lateral femoral cutaneous nerve as in meralgia paraesthetica where patients report numbness, paraesthesiae, pain, an/or hyperaesthesia in the anterolateral thigh should be made by the clinician without difficulty²⁴, this may be less easily done in the small percentage of patients where the nerve derives solely from the L2 nerve as was the case in 2.9% of the plexes in this study.

The presence of an accessory obturator nerve has little relevance with regard to differential strength or sensory loss in patients with suspected obturator neuropathy. The pectineus innervated by the accessory obturator nerve normally derives innervation from the femoral nerve but, due to its small size, contributes little to strength loss with muscle testing²⁴. However, unlike the obturator nerve that passes through the obturator foramen, the accessory obturator nerve can be selectively compressed as it

courses over the superior pubic ramus. Compression and subsequent neuropathy of a present accessory obturator nerve is a differential diagnostic option in groin pain due to its innervation of the hip joint.

Perhaps the most important proposed clinical implication relates to the close relationship that even the “normal” lumbar plexus has with the ilio-psoas muscle. This close anatomical relationship is likely even more relevant in those patients where the femoral nerve branches within the substance of the psoas (and the iliacus) muscle. Elvey²⁵ suggested that muscles have a role in protecting neural tissues when these tissues are sensitive to movement or tension, or when they are inflamed. He reported on the gradual muscular contraction noted by the clinician of muscles that overlie or protect the sensitized neural tissues being implicated in the test maneuver. During straight leg raise testing in patients with sciatica, for example, he hypothesized that a point can be reached where neural tissue nociceptors will discharge, resulting in a central nervous system response that causes increased muscular tone in the hamstring group²⁵.

Several studies have reported an association between adverse neural tension in the sciatic nerve and increased facilitation of the hamstring musculature with increased incidence of associated strain injuries. Kornberg and Lew²⁶ reported a correlation between neural mobility and recurrent muscular injuries, and they demonstrated that rehabilitation that included a slump stretch for the sciatic nerve, combined with traditional treatment, was more effective in treating Australian Rules football players with a grade I hamstring strain than traditional treatment alone. Turl and George²⁷ investigated the presence of adverse neural tension in rugby players with a history of repetitive grade I hamstring strain. They noted that 57% of these players had positive slump tests compared to 0% for controls.

This proposed relationship between neural mechano-sensitivity and muscle tension has also been demonstrated in the upper extremity. Balster and Jull²⁸ studied the association between the bra-

chial plexus tension test and upper trapezius muscle activity in asymptomatic subjects. They found that individuals with decreased neural extensibility demonstrated significantly greater upper trapezius muscle activity during brachial plexus tension tests, leading them to suggest that the stretch receptors found in neural structures may lead to a reflexive increase in muscle activity when neural tissue is tensioned.

We propose that limited mobility in the femoral nerve may also lead to protective muscular guarding. In this case and based on the observed close anatomical relationship between the lumbar plexus and this muscle, we assume that the iliopsoas muscle would be involved. With the iliopsoas inflexibility commonly identified in the orthopaedic population, one must consider the possibility that hip flexor facilitation may be a result of increased mechano-sensitivity of the femoral nerve. This proposed relationship might be more relevant in those subjects where anatomical variation of the type noted in this study is present. In the case of decreased hip flexor length, in our opinion neural mechano-sensitivity and its various etiologies need to be considered in the differential diagnosis.

Limitations

Several limitations to this study must be acknowledged. Foremost, the cadavers utilized in this study were embalmed and had an average age of 75.1 years at the time of death. Although one could argue it is unlikely that age and embalming would affect morphology in a manner relevant to the goal of this study, we nevertheless must use caution when generalizing these findings to other age groups.

Also, it must be emphasized that the aim of this study was to describe anatomical variation of the lumbar plexus by investigating nerve morphology. The dynamic relationship between these anatomical variations and adverse neural tension was not studied and weakens the confidence in our proposed clinical implications in this area. Generally, we have to note that all clinical implications

proposed are based solely on a perhaps unwarranted extrapolation of anatomical data.

In this study, we calculated prevalence based on abnormalities as the numerator and the number of plexes as the denominator. Other studies have used cadavers as the denominator. This does not allow a direct comparison of prevalence rates, further limiting our ability to derive clinically useful estimates for pretest probability from the varied data presented in the research literature.

Conclusion

The current study looked at the prevalence of anatomical variations in the lumbar plexus and the six peripheral branches from the origin at the ventral roots of (T12) L1–L4 to the exit from the pelvic cavity. Prevalence of anatomical variation in the individual nerves ranged from 8.8–47.1% with a mean prevalence of 20.1% and included absence of the iliohypogastric nerve, an early split of the genitofemoral nerve into genital and femoral branches, an aberrant segmental origin for the lateral femoral cutaneous nerve, bifurcation of the lateral femoral nerve prior to exiting the pelvic cavity, bifurcation of the femoral nerve into two to three slips separated by psoas major muscle fibers, the presence of a single anterior femoral cutaneous nerve rather than the normal presentation of two separate anterior femoral cutaneous branches, and the presence of an accessory obturator nerve.

Comparison with relevant research literature showed a wide variation of reported prevalence of the anatomical variations noted in this study, thereby not allowing for a confident extrapolation of data on pretest probability that a variation of the lumbar plexus might be present (and clinically relevant) in the patients presenting to our clinic. In addition, with some studies reporting on cadavers and others on plexes, comparison between studies was not always possible.

We discussed the possible diagnostic relevance of the absence of the iliohypogastric nerve, aberrant segmental contribution to the lateral femoral cutaneous nerve, and presence of an acces-

sory obturator nerve. Our main proposed clinical implication concerned the possible role that femoral nerve mechano-sensitivity might play in the increased tension in the iliopsoas muscle often noted clinically. We acknowledge that these proposed clinical implications may be unwarranted extrapolations from our present anatomical study and discussion of basic science research in this area. We propose that further research should be conducted to investigate the relationship between anatomical variation and its effect on patient presentation and differential diagnosis, most specifically with regard to the effect of anatomical variation on neural mechano-sensitivity.

Acknowledgments

The primary author would like to thank Drs. William Boissonnault, Richard Jensen, and Daniel Lofald for guidance, input, and editorial assistance on the original version of this manuscript.

REFERENCES

1. Guyatt G, Haynes B, Jaeschke R, et al. Introduction to the philosophy of evidence-based medicine. In: Guyatt G, Rennie D, eds. *User's Guide to the Medical Literature: A Manual for Evidence-Based Clinical Practice*. Chicago, IL: AMA Press, 2002.
2. Centre for Evidence-Based Medicine. Levels of evidence and grades of recommendation. Available at: http://www.cebm.net/levels_of_evidence.asp. Accessed February 24, 2009.
3. Lake DA. *Physical Therapy Admissions Requirements* [PowerPoint Presentation] Available at: www.aptaeducation.org/images/PTAdmissions_10-03.ppt Accessed February 28, 2009.
4. American Physical Therapy Association. *Normative Model of PT Professional Education*. Alexandria, VA: APTA, 2004.
5. Clemente CD. *Gray's Anatomy*. 30th American ed. Baltimore, MD: Williams & Wilkins, 1985.
6. Moore KL, Dalley AF. *Clinically Oriented Anatomy*. 4th ed. Baltimore, MD: Lippincott, Williams & Wilkins, 1999.
7. Palastanga N, Field D, Soames R. *Anatomy & Human Movement: Structure & Function*.

- 3rd ed. Boston, MA: Butterworth Heinemann, 1998.
8. Sauerland EK. *Grant's Dissector*. 11th ed. Baltimore, MD: Williams & Wilkins, 1994.
9. Linder HH. *Clinical Anatomy*. East Norwalk, CT: Appleton & Lange, 1989.
10. Pratt NE. *Clinical Musculoskeletal Anatomy*. New York, NY: Lippincott, 1991.
11. Sim IW, Webb T. Anatomy and anaesthesia of the lumbar somatic plexus. *Anaesth Intensive Care* 2004;32:178–187.
12. De Ridder VA, De Lange S, Popta J. Anatomical variations of the lateral femoral cutaneous nerve and the consequences for surgery. *J Orthop Trauma* 1999;13:207–211.
13. Erbil KM, Oderoğlu S, Başar R. Unusual branching in lumbar plexus: Case report. *Okajimas Folia Anat Jpn* 1999;76:55–59.
14. Webber RH. Some variations in the lumbar plexus of nerves in man. *Acta Anat* 1961;44:336–345.
15. Grothaus MC, Holt M, Mekhail AO, Ebraheim NA, Yeasting RA. Lateral femoral cutaneous nerve: An anatomic study. *Clin Orthop* 2005;437:164–168.
16. Erbil KM, Sargon FM, Sen F, et al. Examination of the variations of the lateral femoral cutaneous nerves: Report of two cases. *Anat Sci Inc* 2002;77:247–249.
17. Rosenberger RJ, Loeweneck H, Meyer G. The cutaneous nerves encountered during laparoscopic repair of inguinal hernia: New anatomical findings for the surgeon. *Surg Endoscop* 2000;14:731–735.
18. Carai A, Fenu G, Sechi E, Crotti FM, Montella A. Anatomical variability of the lateral femoral cutaneous nerve: Findings from a surgical series. *Clin Anat* 2009;22:365–370.
19. Spratt JD, Logan BM, Abrahams PH. Variant slips of psoas and iliacus muscles, with splitting of the femoral nerve. *Clin Anat* 1996;9:401–404.
20. Jelev L, Shivarov V, Surchev L. Bilateral variations of the psoas major and the iliacus muscles and presence of an undescribed variant muscle-accessory iliopsoas muscle. *Ann Anat* 2005;187:281–286.
21. Jakubowicz M. Topography of the femoral nerve in relation to components of the iliopsoas muscle in human fetuses. *Folia Morphol* 1991;50:91–101.
22. Akkaya T, Comert A, Kendir S, et al. Detailed anatomy of accessory obturator nerve blockade. *Minerva Anestiol* 2008;74:119–122.
23. Tubbs RS, Salter EG, Wellons JC III, Blount JP, Oakes WJ. Anatomical landmarks for the lumbar plexus on the posterior abdominal wall. *J Neurosurg Spine* 2005;2:335–338.
24. Russell SM. *Examination of Peripheral Nerve Injuries*. New York, NY: Thieme, 2006.
25. Elvey RL. The investigation of arm pain: Signs of adverse responses of the physical examination of the brachial plexus and related neural tissues. In: Boyling JD, Palastanga N, eds. *Grieve's Modern Manual Therapy*. 2nd ed. New York, NY: Churchill Livingstone, 1998:577–585.
26. Kornberg C, Lew P. The effect of stretching neural structures on grade one hamstring injuries. *J Orthop Sports Phys Ther* 1989;10:481–487.
27. Turl S, George K. Adverse neural tension: A factor in repetitive hamstring strain? *J Orthop Sports Phys Ther* 1998;27:16–21.
28. Balster SM, Jull GA. Upper trapezius muscle activity during the brachial tension test in asymptomatic subjects. *Man Ther* 1997;2:144–149.