January, 2004

The Personal Digital Assistant (PDA) as a tool for telementoring endoscopic procedures.

Cody K Bumgardner, *University of Kentucky*

The Personal Digital Assistant (PDA) as a tool for telementoring endoscopic procedures.

Alex Gandsas, MD[1], Katherine McIntire, MD, Kevin Montgomery, PhD[2], Cody Bumgardner[1] and Linda Rice[1]

1-Department of Surgery, University of Kentucky, 800 Rose Street Rd. #349 Lexington, KY 40536
2- NASA-Stanford National Center for Biocomputation, Stanford, CA 94305

Abstract: The telementoring of surgical procedures is currently achieved via a wired infrastructure that usually requires sophisticated videoconference systems. This project represents the first step in assessing the potential for using handheld computers as a mobile alternative to current telementoring systems. Specifically, this project compares a handheld computer to a standard CRT monitor regarding their capability to accurately display video images from an endoscopic procedure.

Video images from two previously recorded endoscopic procedures were transmitted from a standard VCR to: 1) a handheld computer (iPAQ 3670 running Pocket PC) via a wireless LAN and 2) a standard CRT monitor via a wired analog connection. The software used on the handheld device was custom designed to allow 320X240 pixel video images to be broadcast in real time. Twenty-three surgical residents who had completed an endoscopy rotation were randomized to watch one of the two videotaped endoscopic procedures on the hand held computer or on the CRT monitor. After viewing the procedure, a ten-question quiz was used to assess the ability of each participant to recognize several anatomic landmarks. The result of each questionnaire was expressed as the percentage of correct responses. Using a crossover design, each participant then viewed the other videotaped procedure using the alternate device and completed a second quiz. The mean test score for each device was calculated, and these data was analyzed using a Student T test .

The observed difference between the mean test score associated with the handheld device (77.93 ±11.26) and the CRT monitor (81.30 ±12.54) was not statistically significant ($p<0.41$). In addition, regardless of the device used, scores corresponding to video tape one were significantly higher than those recorded for video tape two (84.35±9.92 vs. 74.35±11.61; $p<0.01$)

All participants were able to recognize anatomic landmarks equally well when viewing broadcasted endoscopic procedures on a handheld display or a standard CRT monitor. Handheld computers may have a role in telementoring residents who are performing endoscopic procedures. Further research is needed to evaluate the integration of handheld devices into telementoring and robotic system to perform surgical procedures.

1- Introduction

Surgical telementoring refers to the process by which one surgeon remotely assists/teaches another surgeon who is actively performing a surgical procedure. Currently, such sessions rely on

two-way, full duplex audio and video transmission between standard CRT monitors via sophisticated computer hardware wired to a local network. Several groups have reported successful experiences conducting such telementoring sessions during surgical procedures.[1-3] However, the wired nature of these systems requires that the expert be on-site during the procedure thus limiting the practical benefit. Having an on-site, expert consultant close to the videoconference unit during a medical emergency is a challenge, one that may be mitigated by developing wireless telementoring systems that will allow the expert to carry the display unit/telementoring interface in his/her pocket.

At the University of Kentucky, we tested a system in 2001 that combined streaming video technology and wireless transmission protocols and successfully broadcasted live surgery in real time to handheld computers.[4] Study participants were able to identify surgical anatomy and follow the procedure in its entirety. However, low frame rate (15 frames per second) and a 30-second transmission delay limited the system's application to educational purposes such as broadcasting lectures and Grand Rounds.

We have since incorporated customized software, and our wireless system is now capable of transmitting live video at a higher frame rate with less than a 1-second delay (NASA Ames, Biocomputation). We believe that our improved system may provide the foundation for wireless telementoring in which a handheld computer serves as the interface that links the expert to the trainee in the operating/procedure room. Extensive research will be required including software development to realize our vision into a fully operational telementoring tool. This project represents the first step. The objective of this study is to determine whether the images transmitted wirelessly to a handheld computer are adequate to allow a physician to accurately identify the anatomy and thus allow a surgeon to potentially telementor during an on-going procedure on the basis of these images alone.

2- Materials and Methods:

Using a randomized, cross-over design, this study compared the ability of surgical residents to identify anatomical structures displayed on a standard monitor versus a handheld computer screen during an endoscopic procedure that was transmitted from a standard VCR via a wired or wireless transmission system, respectively. The study population consisted of consenting surgical residents who had completed an endoscopy rotation. Two previously recorded endoscopic procedures were used. Tape 1 contained a normal esophago-gastro-duodenoscopy, and Tape 2 contained the upper endoscopy of a patient who developed stenosis of the stoma following gastroplasty for morbid obesity. The video images were transmitted without audio from the VCR to the standard CRT monitor (13" Sony PVM-1343 MD Trinitron) using a standard wired analog connection and to the handheld computer (iPAQ 3670 running on a Windows Pocket PC 2002 platform) via a wireless LAN (see Figure 1). The iPAQ was equipped with a wireless card (W110 Wireless PC card), a 206 MHz Strong Arm Processor, a 12-bit color reflective thin-film-transistor (TFT) with 0.24mm Dot pitch and 64 MB RAM/16 MB ROM of memory. The software used on the iPAQ was customized to allow 320x240 pixel JPEG images to be broadcast in real time at 28 frames per second. A 1Gig Pentium 4 server computer running on a Windows 2000 platform was assigned to receive and digitize analog signals from the VCR using an internal video capture card (Winnov's Videum 1000 Plus). The digital video signal was then encoded to stream at 150 Kbps. The server was connected to the University LAN, and a wireless access point (WL 410 Wireless SMB, Compaq

Inc) was used to establish a wireless link between the server and the iPAQ using the 802.11b wireless protocol.

Using a randomization procedure, each participant was first assigned to a viewing device, CRT or iPAQ, and to a video, Tape 1 or Tape 2. Each participant was then given a ten-question quiz to be completed while viewing the corresponding Tape. Both videos contained ten anatomical landmarks marked by a black arrow and a number (1-10), which corresponded to a 5-option multiple choice quiz question asking for the name of the highlighted structure. Participants were allowed to pause the tape while answering each question. After viewing the tape and completing the corresponding quiz, each participant was then asked to repeat the procedure viewing the other video on the alternate viewing device. The result of each quiz was expressed as the percentage of correct responses. The mean test score for each viewing device was calculated, and these data were analyzed using a Student T test.

This study protocol was reviewed and approved by the University Institution Review Board (IRB).

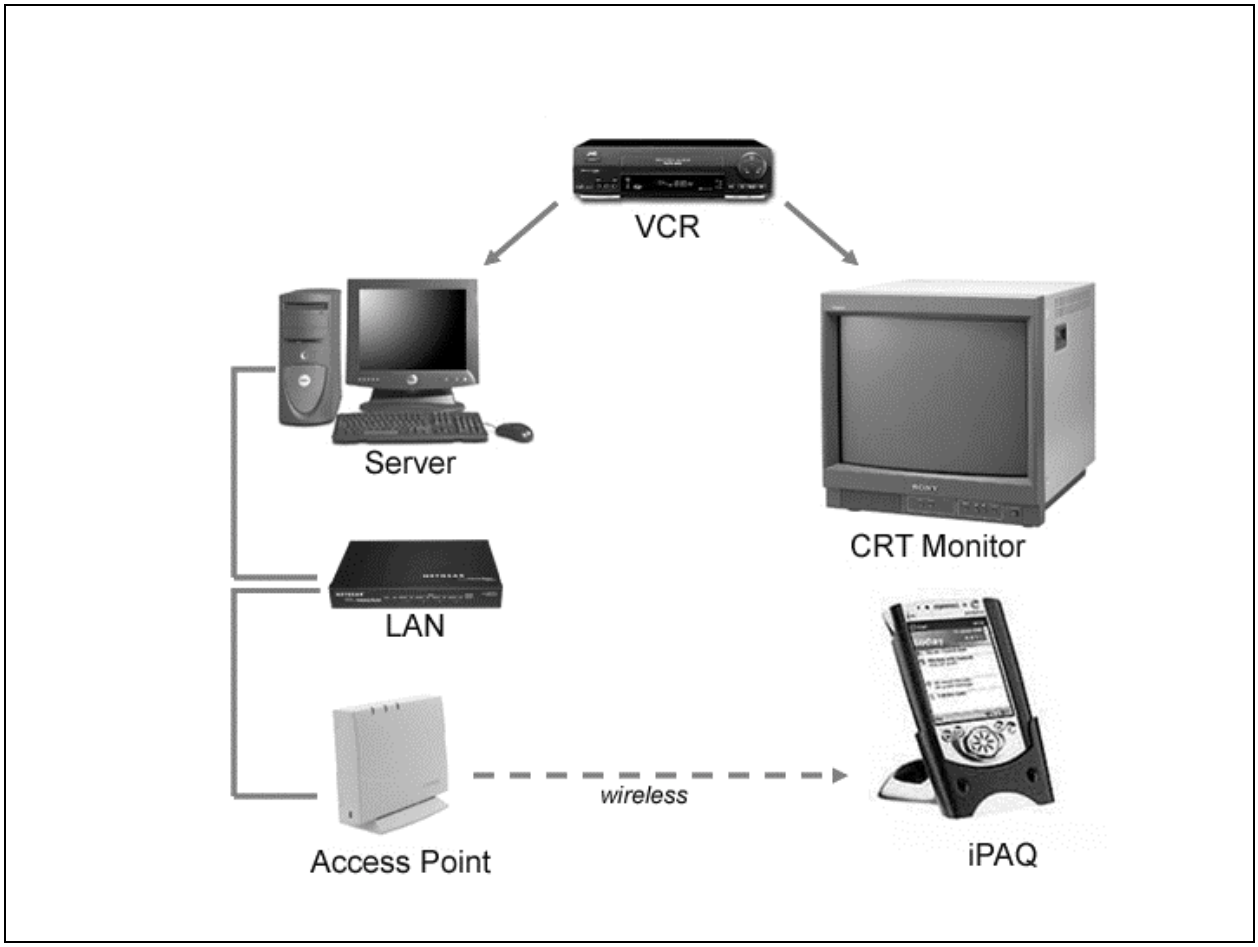

Figure 1: CRT and iPAQ set-up for wired and wireless transmission

Results:

Twenty-three participants completed the study. Without regard to the viewing device used, the mean test score for Tape 1 was significantly higher than that for Tape 2 (84.35±9.92 vs. 74.35±11.61; $p<0.01$). However, the observed difference between the mean test scores associated with the iPAQ and the CRT monitor (77.93±11.26 vs. 81.30±12.54) was not statistically significant ($p<0.41$).

Comments:

The study participants were able to recognize anatomic landmarks equally well when endoscopic procedures were viewed on the handheld computer via a wireless connection as compared to the standard, wired CRT monitor used in current telementoring systems. This study thus gives preliminary validation for further research to develop telementoring systems that incorporate handheld devices. Mobile computers may have yet another niche in the medical field.

Mobile computers were introduced in 1993, and their use became widespread by the late 1990s. The ability to instantly access information via a portable, light weight and user-friendly device is the basis for the overwhelming success of this technology. The mobility combined with the data storage capability and their relatively low cost made handheld computers especially attractive tools for health care workers who could now retrieve and manage patient information without being confined to a desktop terminal. Although the concept of teaching or assisting on a procedure across long distances is not novel, it was not until the beginning of the 21st century that the use of fast communications networks opened a new opportunity for telemedical applications. Furthermore, with the development of more affordable high-speed bandwidth such as the Internet or Internet 2, telemedical applications actually evolved to accommodate the needs of healthcare providers. Wireless technology was added to handheld computers in 2001, making up-to-date information available in real time. Using low-cost technology, physicians were now able to download patient data including laboratory results and radiographs and perform tasks such as writing/sending prescriptions. It is estimated that 50% of physicians will be using a PDA as a patient management tool by the year 2005.[5]

We believe that handheld computers could potentially be used as a tool to remotely assist during a surgical procedure. In our study, video images were rendered on the iPAQ screen with minimal latency (less than 1 second) when compared to images rendered on the CRT monitor. Using a handheld computer with more central processor unit (CPU) power and memory may further reduce this minimal time difference. New Pocket PC devices are equipped with a new 400MHz microprocessor and up to 128 MB of RAM. The video output on the iPAQ used in this study is based on TFT, which allows a backlit color display up to 480 X 320 pixel resolution and a 16 bit color (thousands of color). Despite the differences in video resolution, pixel depth, and data transfer rates between the handheld screen and the CRT monitor, video images were adequate to allow residents to accurately recognize anatomical landmarks in both systems.

We have demonstrated that seamless wireless transmission of live surgery to handheld computers is possible and that the resulting images seem to be adequate for clinical use. Our next goal is to

develop a system based on handheld technology embedded with tele-illustrator technology that can establish two-way audio/video transmission to actively assist during a procedure. By using the handheld stylus, the expert would be able to guide another surgeon and walk him/her through the procedure in a safe manner. Clearly, further research is needed to evaluate the integration of handheld devices into telementoring and robotic systems to perform surgical procedures.

References:

[1] Link RE; Schulam PG; Kavoussi LR. Telesurgery. Remote monitoring and assistance during laparoscopy. Urol Clin North Am. 2001; 28(1): 177-88

[2] Schneider Ushiyama T; Suzuki K; Aoki M et al. Laparoscopic adrenalectomy using telementoring system. Nippon Hinyokika Gakkai Zasshi. 2003; 94(5): 582-6

[3] Rodrigues Netto N Jr; Mitre AI; Lima SV et. al. Telementoring between Brazil and the United States: initial experience. J Endourol. 2003; 17(4): 217-20

[4] Gandsas A, McIntire K, George IM, Witzke W. et. Al. In Westwood et al: Wireless live streaming video of laparoscopic surgery: a bandwidth analysis for handheld computers. Stud Health Technol Inform 82:150-154, 2002.

[5] Bertling CJ; Simpson DE; Hayes AM et. al. Personal digital assistants herald new approaches to teaching and evaluation in medical education. WMJ. 2003; 102(2): 46-50