1992

Intestinal Adenocarcinoma of the Ileocecal Junction in a Chicken

James R. Andreasen, Jr., *Oregon State University*
Claire B. Andreasen, *Oregon State University*

AVIAN DISEASES 36:799–802, 1992

Case Report—

Intestinal Adenocarcinoma of the Ileocecal Junction in a Chicken

James R. Andreasen, Jr., and Claire B. Andreasen

Veterinary Diagnostic Laboratory, College of Veterinary Medicine, Oregon State University, P.O. Box 429, Corvallis, Oregon 97339

Received 9 December 1991

SUMMARY. An 89-week-old male chicken was presented with signs of depression, emaciation, and weakness. At necropsy, a stricture was found at the ileocecal junction that resulted in blockage and dilation of the ileum proximal to the stricture. Histologically, neoplastic epithelial cells that contained mucin had invaded the intestinal wall and produced a fibrous connective tissue reaction. The lesion was diagnosed as scirrhous intestinal adenocarcinoma.

RESUMEN. *Reporte de Caso*—Adenocarcinoma intestinal en la unión íleocecal en pollos. Un pollo macho de 89 semanas de edad estaba presentando signos de depresión, emaciación y debilidad. A la necropsia se le encontró una estructura en la unión íleocecal que producía bloqueo y dilatación del intestino delgado proximal. Histológicamente se observaron células epiteliales que contenían mucina que habían invadido la pared intestinal y producido una reacción del tejido conectivo fibroso. La lesión fue diagnosticada como un adenocarcinoma intestinal escirro.

Intestinal carcinoma is one of the most uncommon neoplasms of the chicken (1,4). Intestinal adenocarcinoma must be differentiated from metastatic oviductal or ovarian carcinoma by demonstrating that no primary oviductal or ovarian tumor exists and that the tumor of the intestine originates from intestinal mucosal epithelium or glands, rather than growing inward from the serosal surface of the intestine (1,8).

Feldman and Olson (3) reported a single case of adenocarcinoma of the ileocecal junction, without metastasis, in a 2-year-old white leghorn hen, which caused a partial obstruction of the intestine. Campbell (1) cited another case of adenocarcinoma involving the ileocecal junction reported by Joest and Ernesti in 1916. Guerin (5) described several small-intestinal tumors of chickens, including one that involved the ileocecal junction. Turk *et al.* (10) reported small-intestinal dilation proximal to a stricture created by intestinal adenocarcinoma 65 cm distal to the pylorus in an aged adult barred rock hen.

The present report describes an adenocarcinoma of the ileocecal junction causing blockage of the intestine in an 89-week-old male DeKalb DK table-egg breeder chicken.

CASE REPORT

Case history. A male chicken was culled from a breeder flock of approximately 11,000 eighty-nine-week-old DeKalb DK chickens because its appearance indicated that it was not actively breeding. This chicken was hunched over, depressed, emaciated, and weak. Its comb and wattles were shrunken and yellowish. Dried fecal material adhered to feathers around the vent.

Necropsy. The chicken was euthanatized by cervical dislocation. At necropsy, a dilated segment of small intestine was found proximal to a 0.5-cm-long stricture at the ileocecal junction (Fig. 1). The intestine at the stricture felt indurated. The dilation, extending proximally from the stricture, was approximately 12 cm long

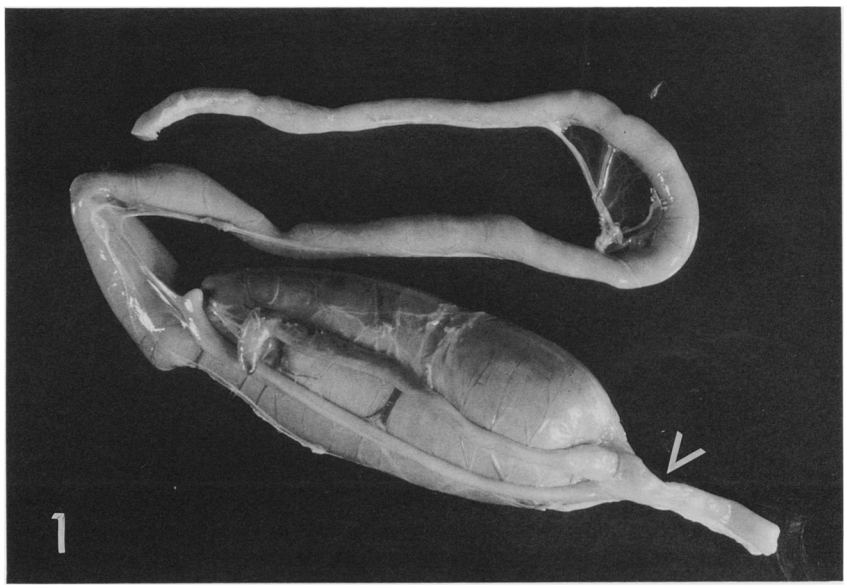

Fig. 1. Section of dilated small intestine proximal to a stricture (arrowhead) caused by an intestinal adenocarcinoma at the ileocecal junction. The empty ceca may be seen attached to the ballooned section of ileum.

and 4–5 cm in diameter. The dilated segment of intestine was thin-walled and contained greenish-black fluid. The intestine proximal to the dilation was small in diameter and contained little digested feed material. The colon distal to the dilation was empty. The ceca were shrunken and contained little material (Fig. 1). The mucosal surface of the stenotic section of intestine appeared normal. No intestinal polyps were found.

The liver was uniformly brown. The gall bladder was enlarged and distended. The crop and gizzard both contained small amounts of feed. Testes were smaller than would be expected in a normal, actively breeding rooster but were not totally involuted. Other viscera, including heart, lungs, kidneys, proventriculus, and gizzard appeared normal at necropsy.

Histology. Tissues were fixed in 10% neutral buffered formalin, embedded in paraffin, sectioned at 5 μm, and stained with hematoxylin and eosin. Histologic sections of ileocecal junction contained acinar and aggregate formations of neoplastic epithelial cells that extended from the lamina propria, through the submucosa and muscularis, to the muscle wall adjacent to the serosal surface (Fig. 2). The neoplastic cells appeared to arise from the intestinal glands. These cells were pleomorphic with round-to-oval vesicular nuclei and periodic acid–Schiff-positive mucinous material within the cytoplasm (Fig. 3). In the submucosa and muscularis externa, neoplastic cells were often surrounded by a scirrhous reaction. Additionally, one Peyer's patch contained acinar formations of the same neoplastic cells. The mitotic index of the tumor cells varied from moderate to high. The spleen and kidney contained no significant lesions. The liver contained increased numbers of bile ducts with scattered bile accumulation. The intestinal mass was classified as an intestinal adenocarcinoma with scirrhous reaction.

DISCUSSION

Several of the reported primary intestinal adenocarcinomas of chickens appearing in the literature have been questioned by Campbell (1) and Jackson (7). Those investigators suggested that the questionable tumors appeared to be metastatic primary carcinomas of the female reproductive tract—which cannot be the case in the present report involving a male chicken. Aside from the factor of sex, the tumor in the present case was continuous with intestinal epithelium and glands. The lesion extended from the lamina propria into the muscularis rather than affecting the serosa with extension into the

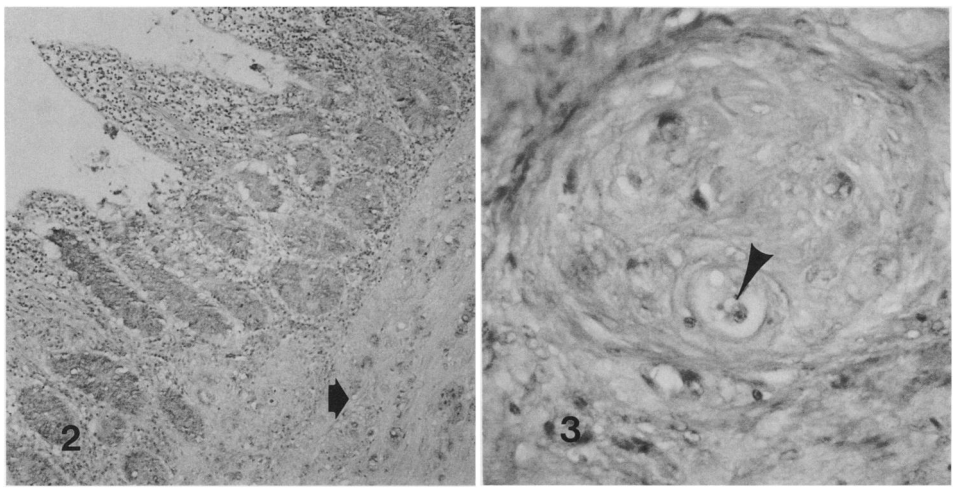

Figs. 2 and 3. 2) Individual and aggregates of neoplastic epithelial cells (short arrow) infiltrating the submucosa and muscularis of the intestine. Mucosal surface exhibits autolysis of enterocytes. H&E. 25×. 3) Individual adenocarcinoma cells (long arrow) surrounded by a scirrhous reaction. H&E. 400×.

muscularis. Those factors, in the absence of any indication of tumor in any other organ, are sufficient to justify the diagnosis of primary intestinal adenocarcinoma.

Intestinal dilation in the present case occurred secondary to stenosis of the ileocecal junction. Annular stenotic tumors of the intestinal tract are usually malignant. The scirrhotic reaction, which results in stenosis, may be caused by the neoplastic cells inducing formation of fibrous connective tissue and by obstruction of lymphatics (6). Stenotic carcinomas are usually 1–2 cm long in carnivores and sheep and may be 5 cm long in cattle (6). In the present case, the stenotic lesion was approximately 0.5 cm long. Presence of dried fecal material on feathers around the vent of the chicken in this case suggests diarrhea, which may be seen in carnivores with stenotic carcinomas of the lower intestinal tract (6).

The intestinal adenocarcinoma in the present case was located at the ileocecal junction, which is a common site for adenocarcinomas in ruminants and cats (6). As there are at least three other reports in chickens of adenocarcinoma involving the ileocecal junction (1,3,5), that location appears to be a common site for the tumor in chickens. In other domestic animal species, intestinal carcinomas are usually solitary but have metastatic potential. At necropsy, no metastasis was found in the present case.

Intestinal adenocarcinomas appear to be as uncommon in other avian species as in chickens. No intestinal adenocarcinomas are mentioned in one survey of tumors of pet bird species (2), and another survey describes only cases of cloacal adenocarcinoma (9). No other chickens in the flock from which the present case originated are known to have developed intestinal adenocarcinomas. The etiology of avian intestinal adenocarcinomas is not known.

REFERENCES

1. Campbell, J. G. Tumours of the fowl. William Heinemann Medical Books Ltd., London. pp. 134–138. 1969.

2. Campbell, T. W. Neoplasia. In: Clinical avian medicine and surgery. G. J. Harrison and L. R. Harrison, eds. W. B. Saunders Co., Philadelphia. pp. 500–508. 1986.

3. Feldman, W. H., and C. Olson. Neoplastic diseases of the chicken. In: Diseases of poultry, 5th ed. H. E. Biester and L. H. Schwarte, eds. Iowa State University Press, Ames, Iowa. pp. 863–924. 1965.

4. Fredrickson, T. N., and C. F. Helmboldt. Tumors of unknown etiology. In: Diseases of poultry, 9th ed. B. W. Calnek, H. J. Barnes, C. W. Beard, W. M. Reid, and H. W. Yoder, Jr., eds. Iowa State University Press, Ames, Iowa. pp. 459–470. 1991.

5. Guerin, M. Tumeurs spontanées de la poule. Tumeurs d'organes thoraco-abdominaux. In: Tu-

meurs spontanées des animaux de laboratoire. Legrand, Paris. pp. 153–180. 1954.

6. Head, K. W. Tumors of the alimentary tract. In: Tumors in domestic animals, 3d ed. J. E. Moulton, ed. University of California Press, Berkeley, Calif. pp. 347–435. 1990.

7. Jackson, C. The incidence and pathology of tumours of domesticated animals in South Africa. Onderstepoort J. Vet. Sci. Anim. Ind. 6:3–460. 1936.

8. Kajigaya, H., A. Ohta, H. Suzuki, T. Hase, H. Yamashina, M. Sugiyama, and M. Isoda. Estradiol receptors and ovalbumin in adenocarcinoma of hens. Avian Dis. 30:219–220. 1986.

9. Petrak, M. L., and C. E. Gilmore. Neoplasms. In: Diseases of cage and aviary birds, 2nd ed. M. L. Petrak, ed. Lea & Febiger, Philadelphia. pp. 606–637. 1982.

10. Turk, J. R., A. L. Forar, and A. M. Gallina. Intestinal adenocarcinoma in a chicken. Avian Dis. 24: 507–509. 1980.